

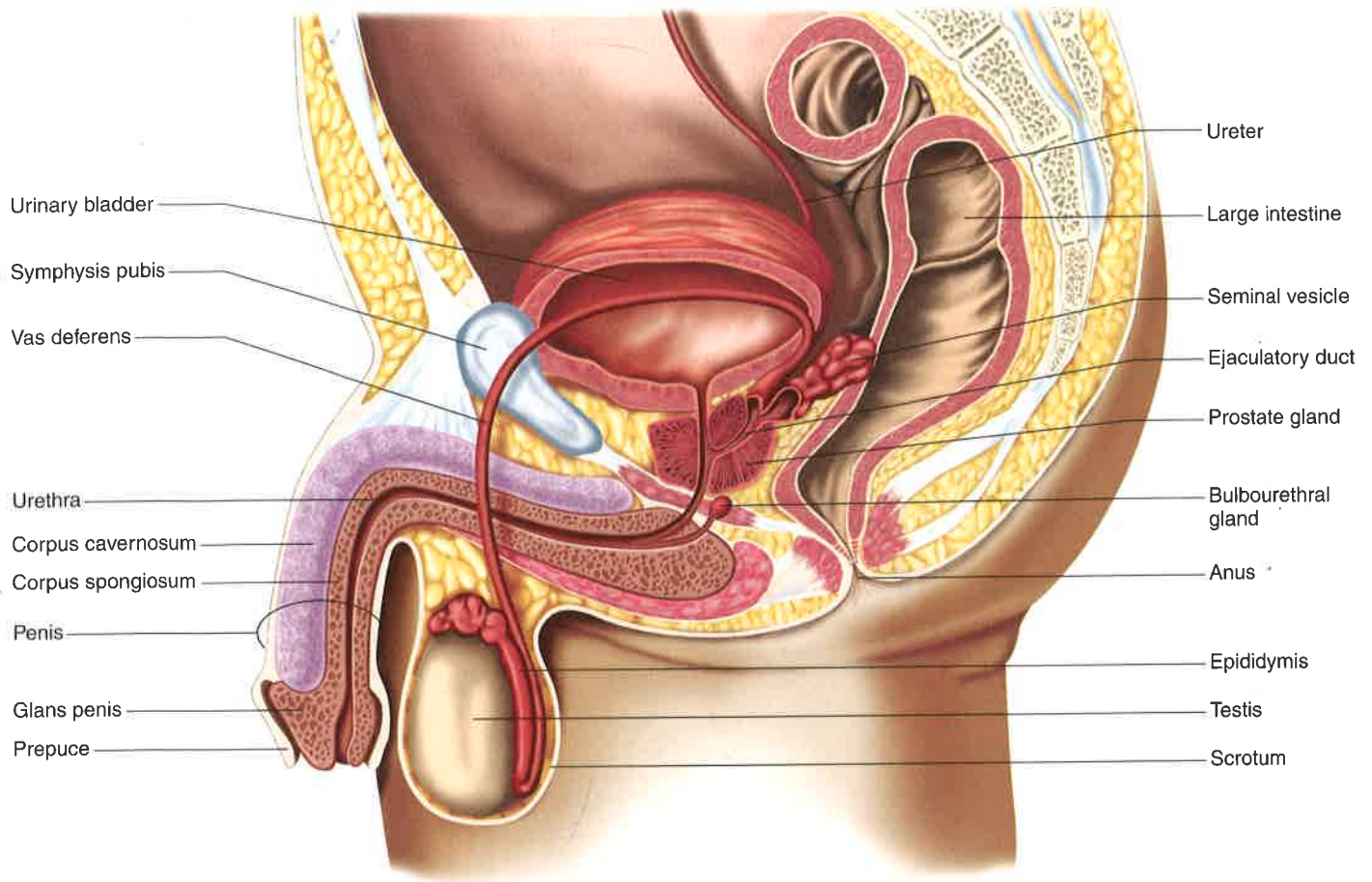Figure 19.1

Male reproductive organs (sagittal view). The paired testes are the primary sex organs, and the other structures, both internal and external, are accessory sex organs.

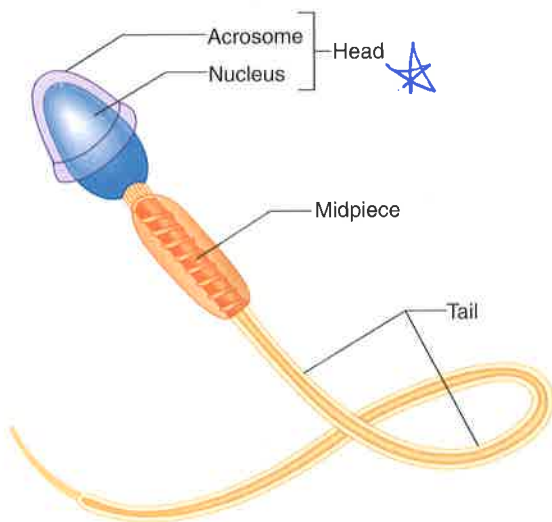


Figure 19.3

Parts of a mature sperm cell.

