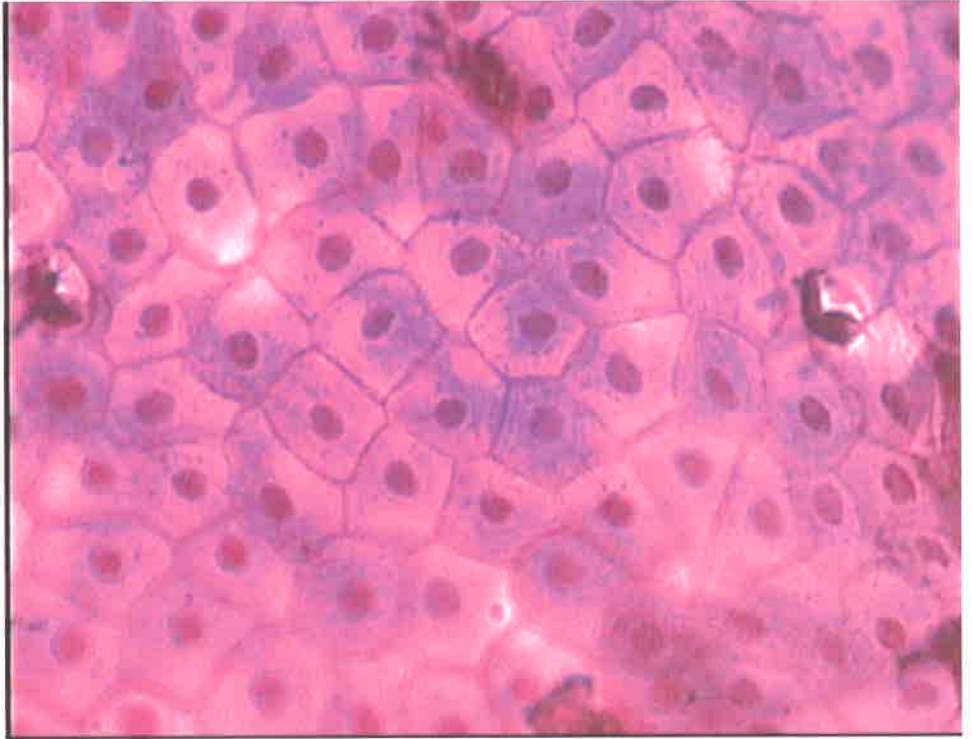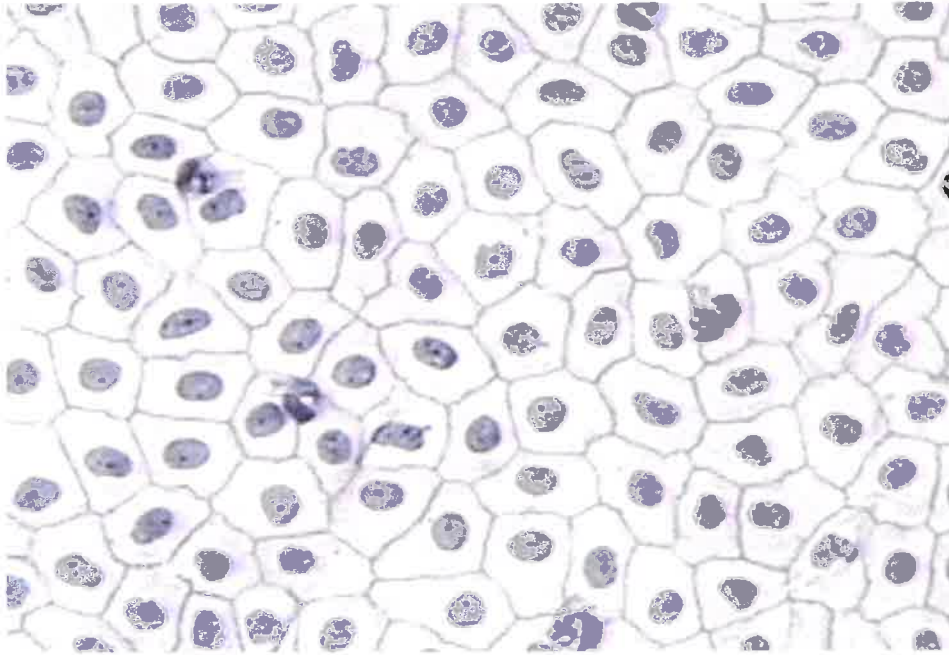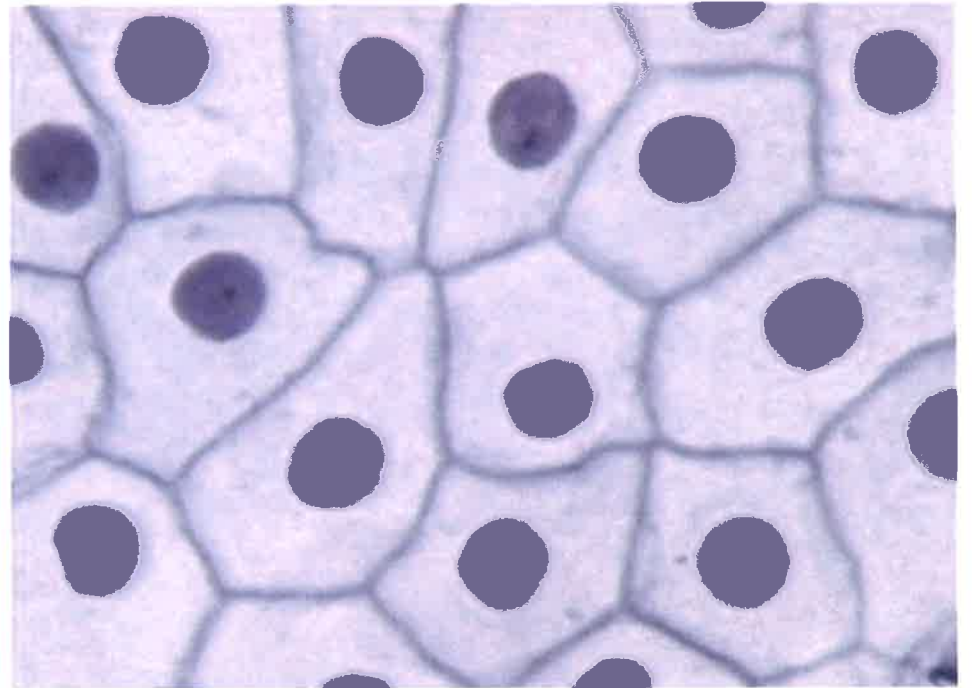
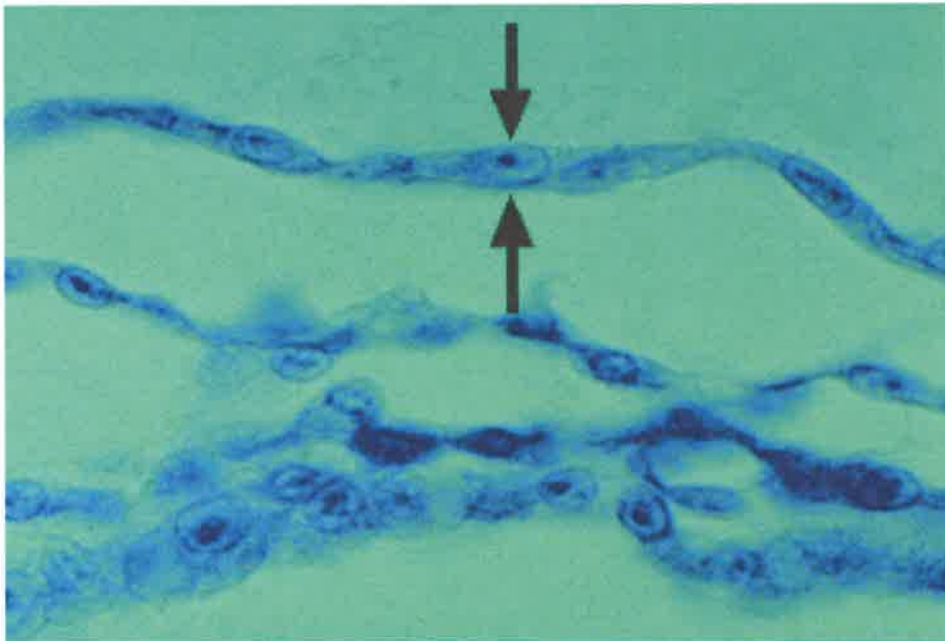
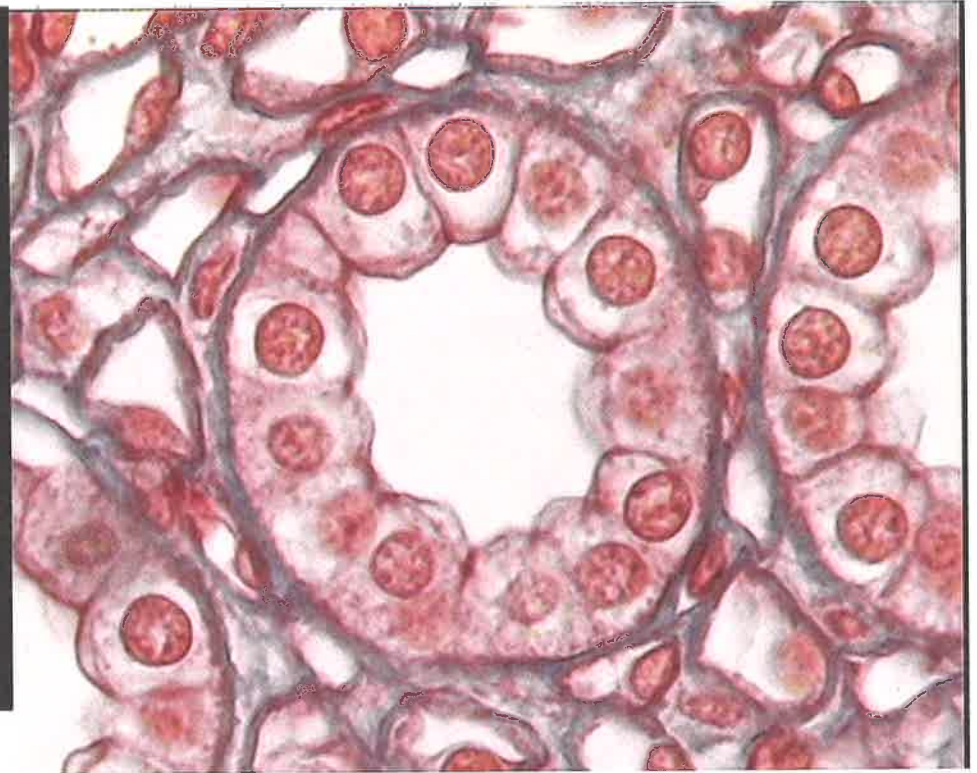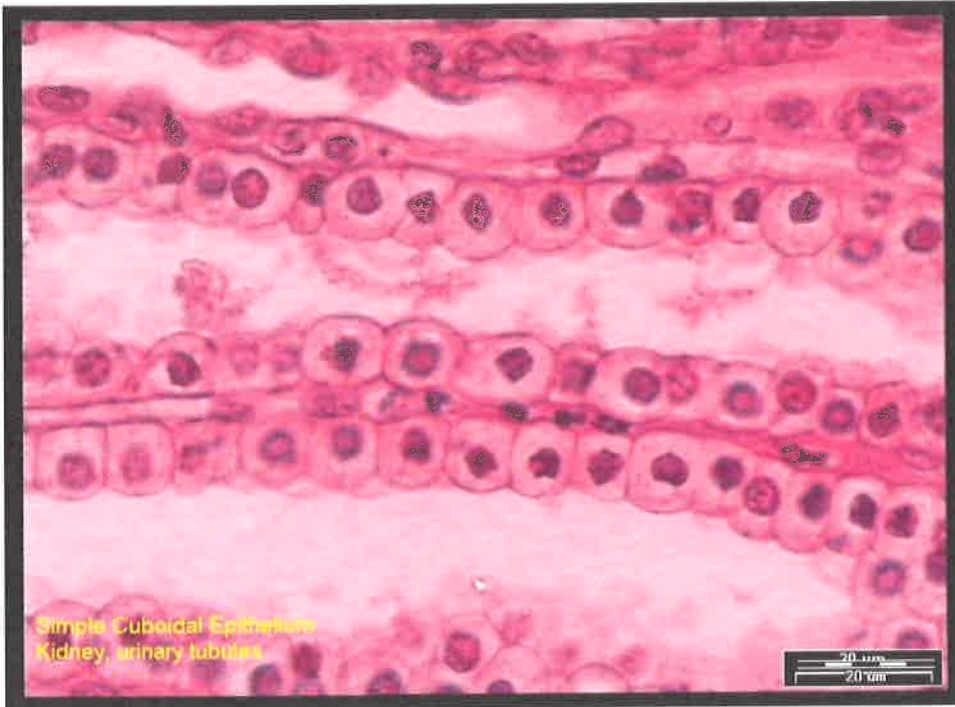
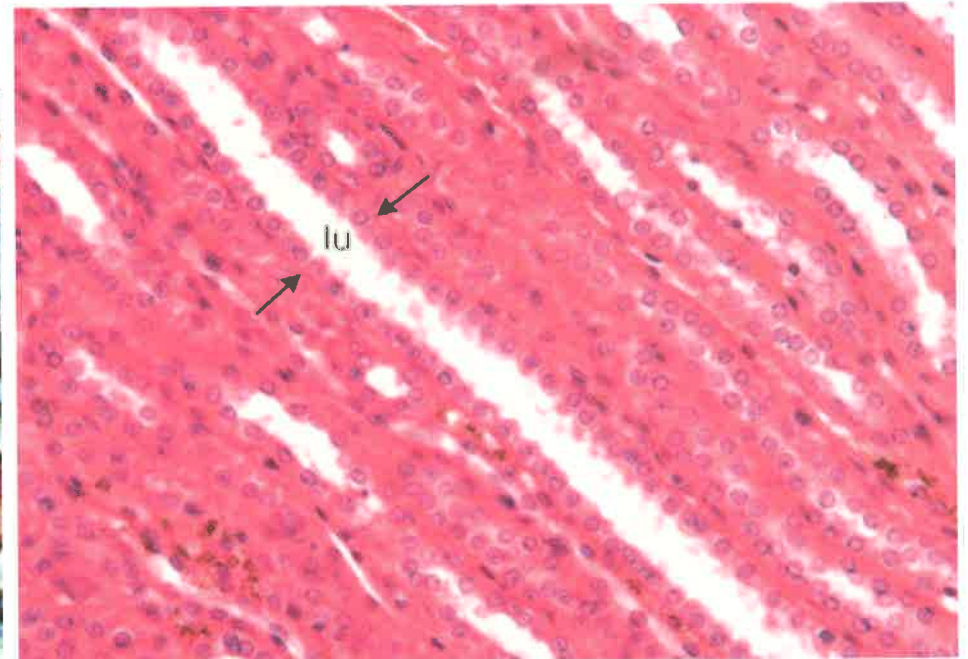
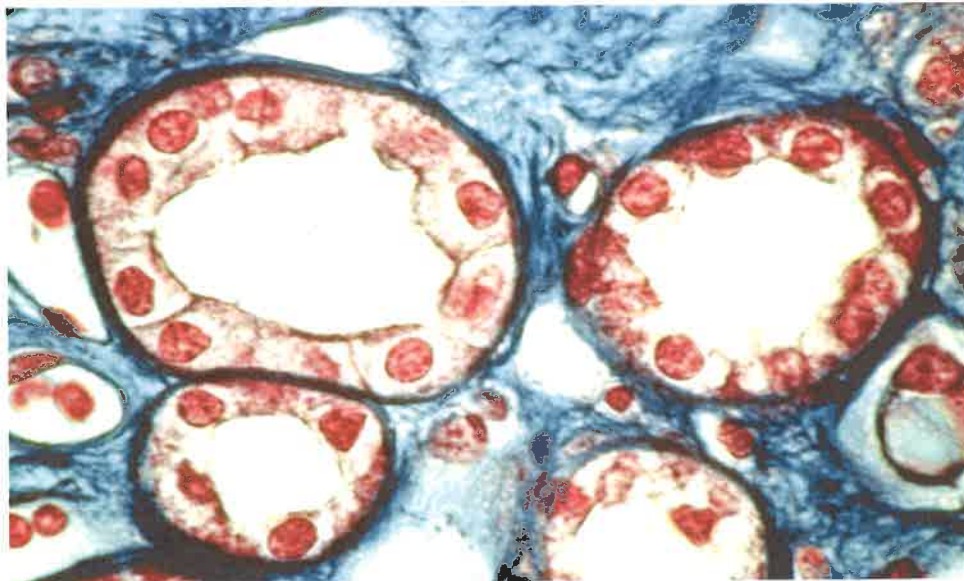


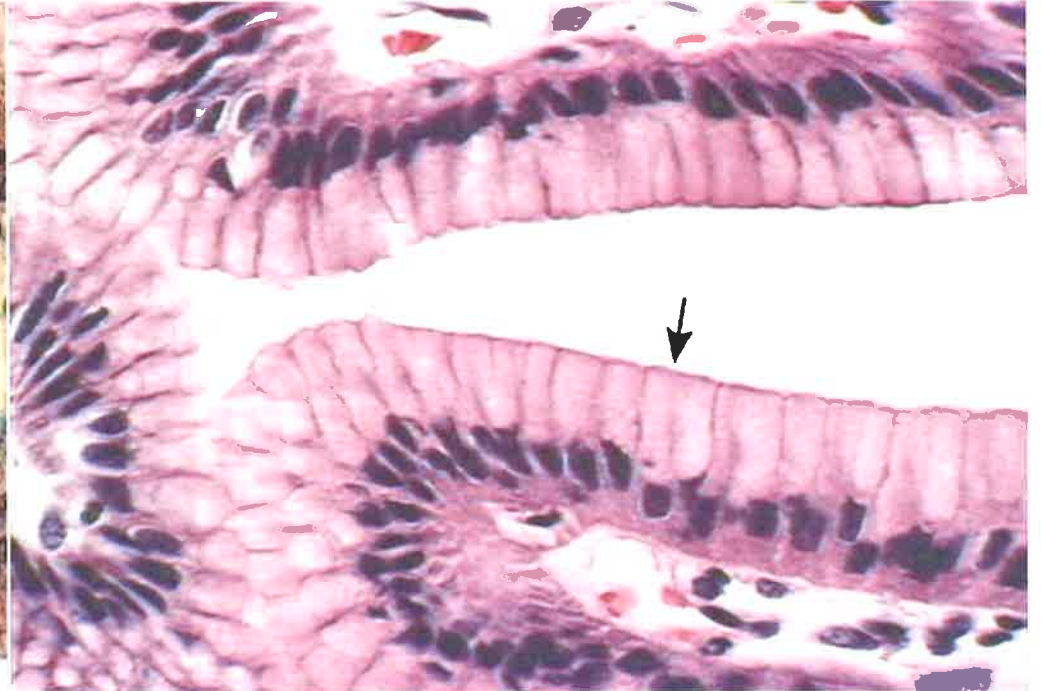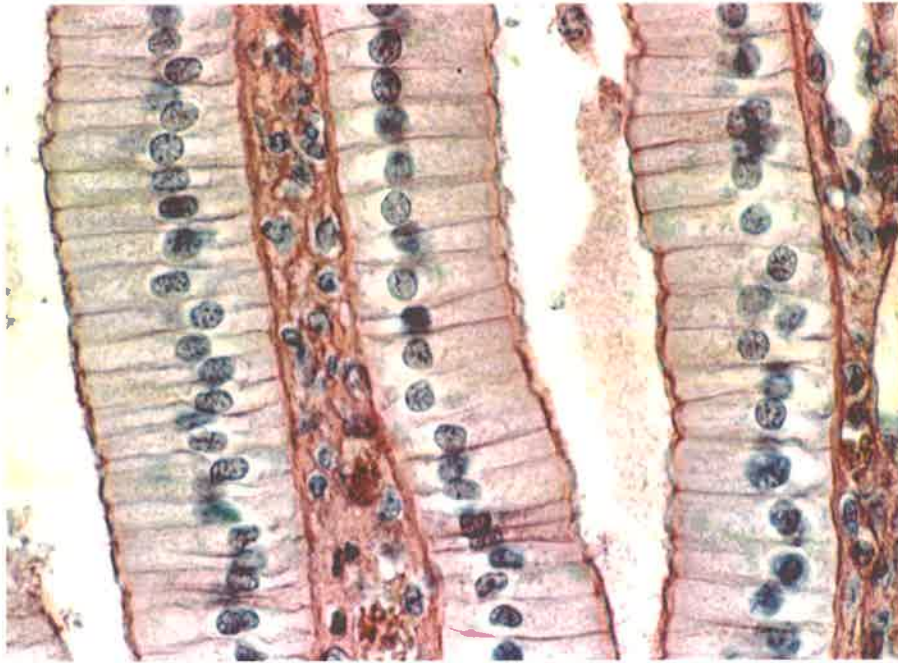
Simple Squamous Epithelial Tissue



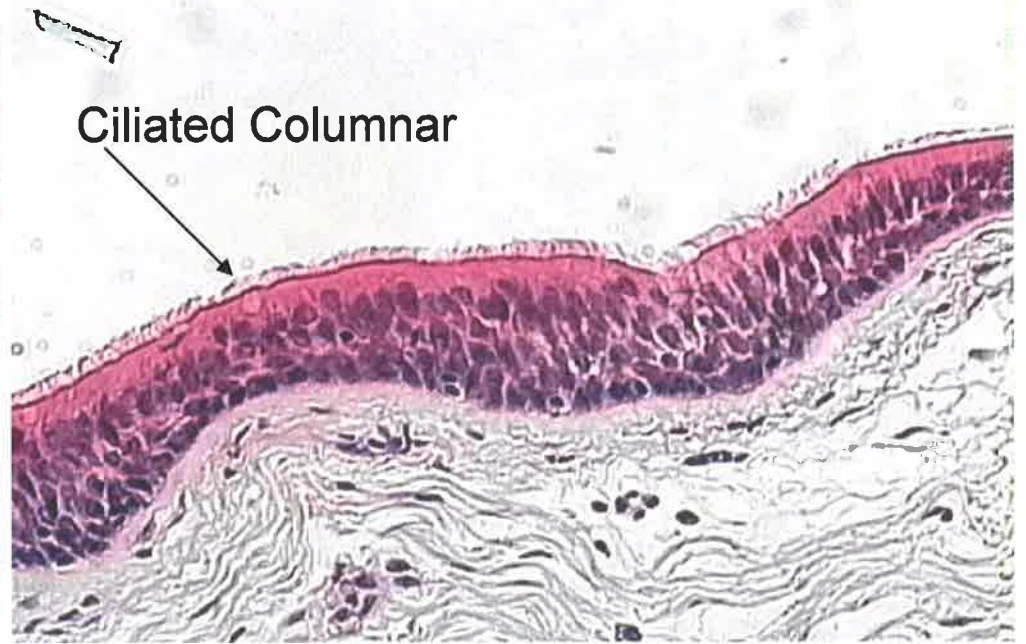
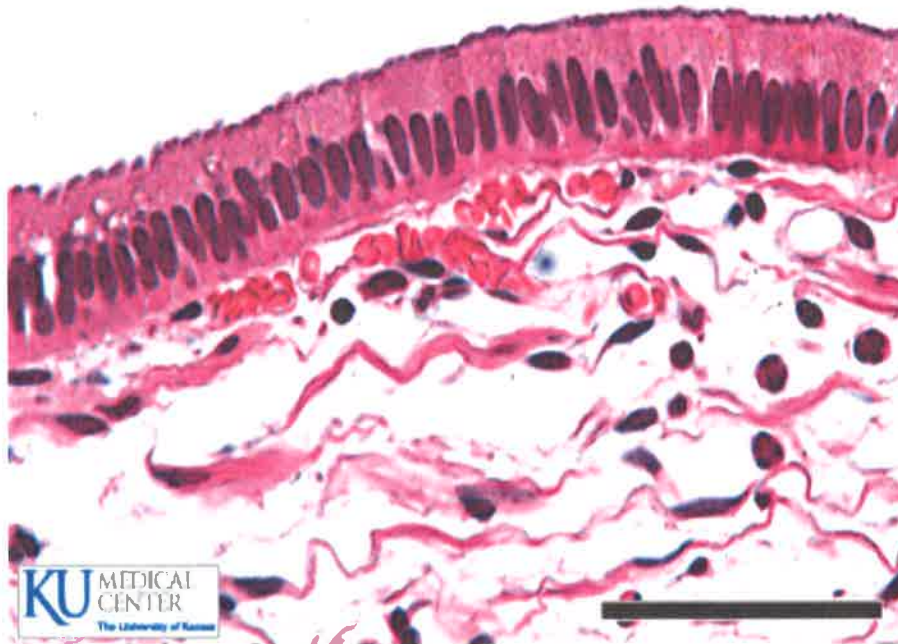


Simple Cuboidal Epithelial Tissue

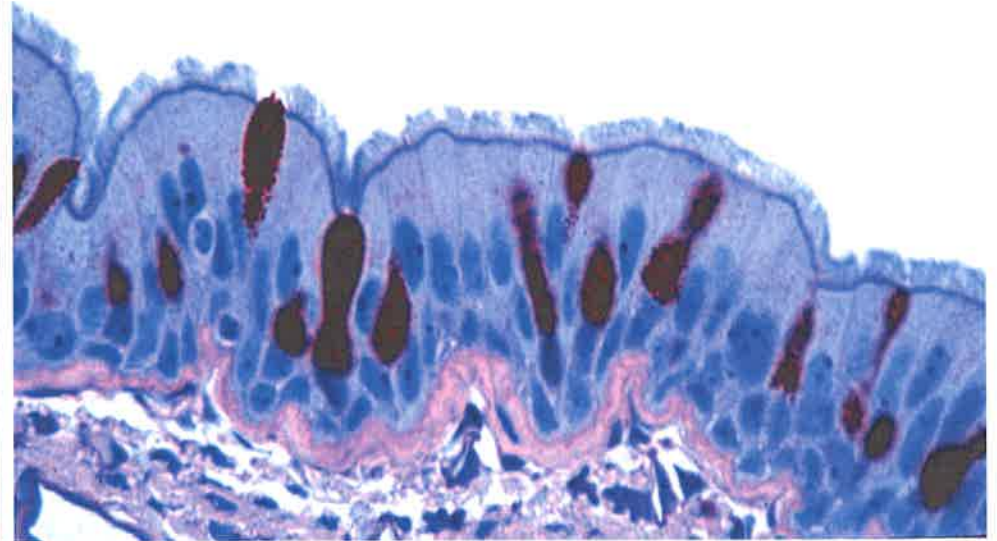
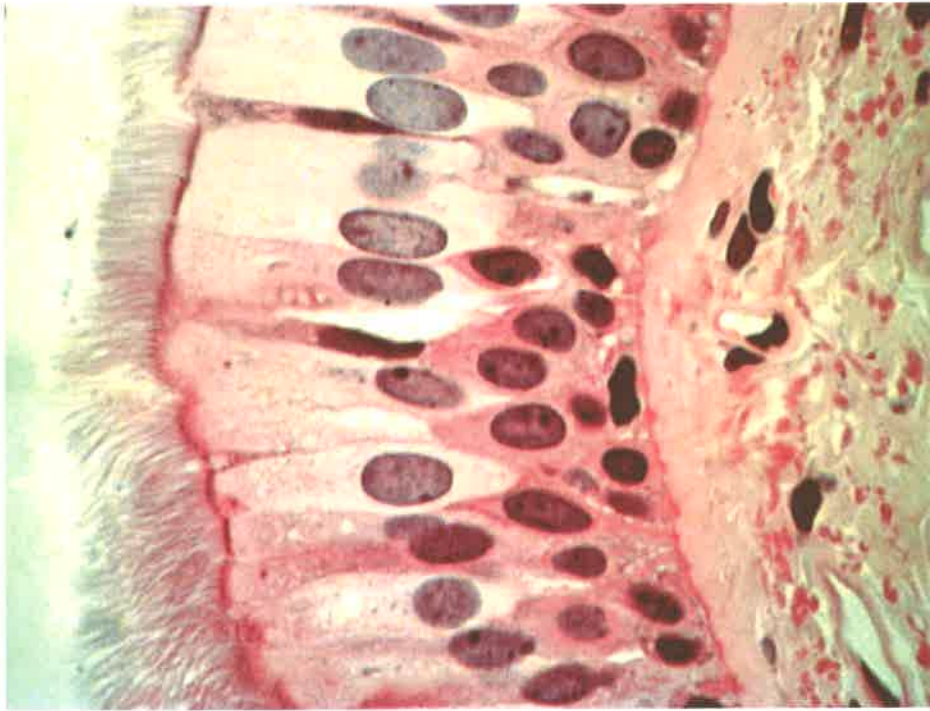




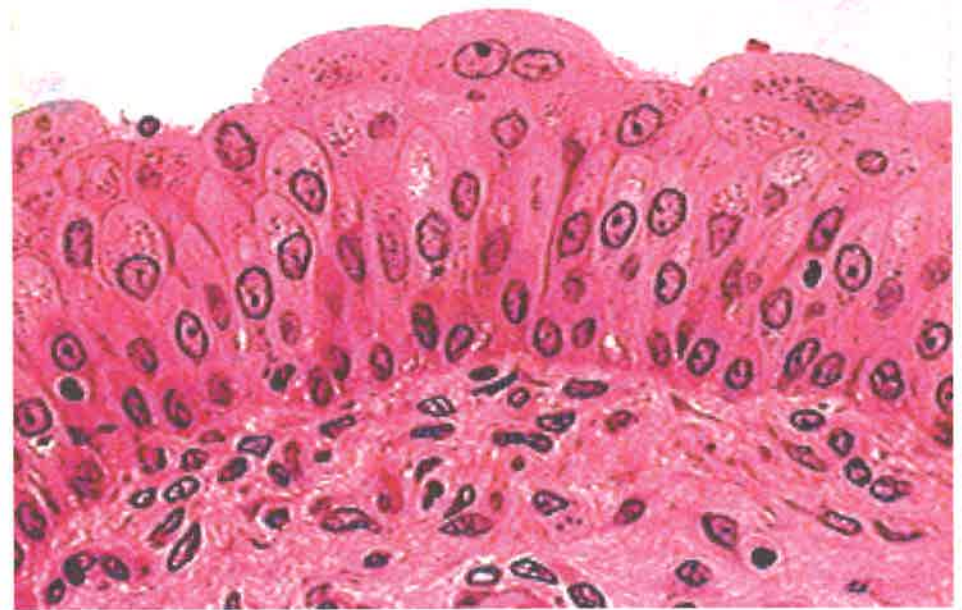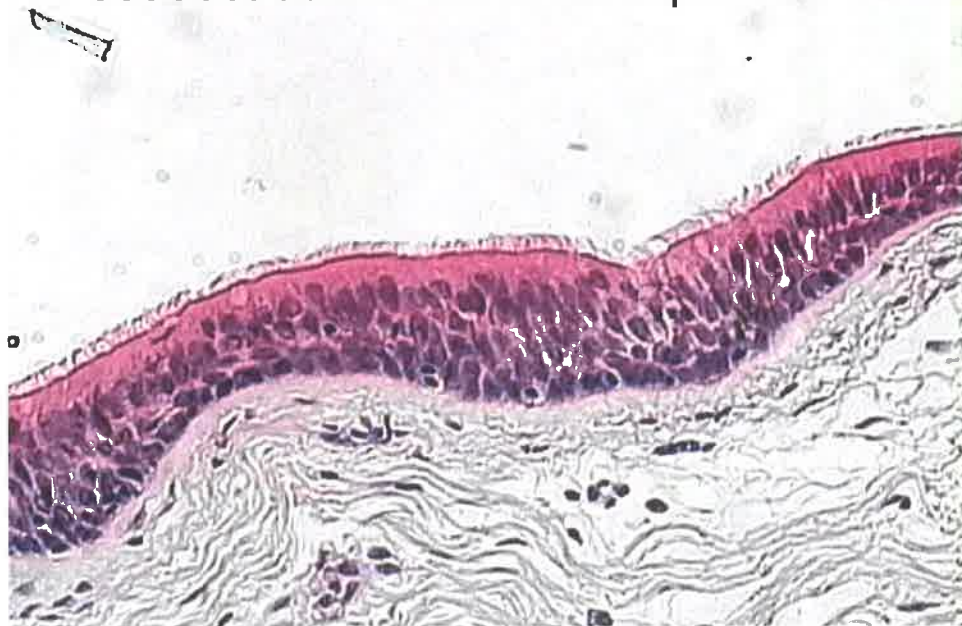Simple Columnar Epithelial Tissue

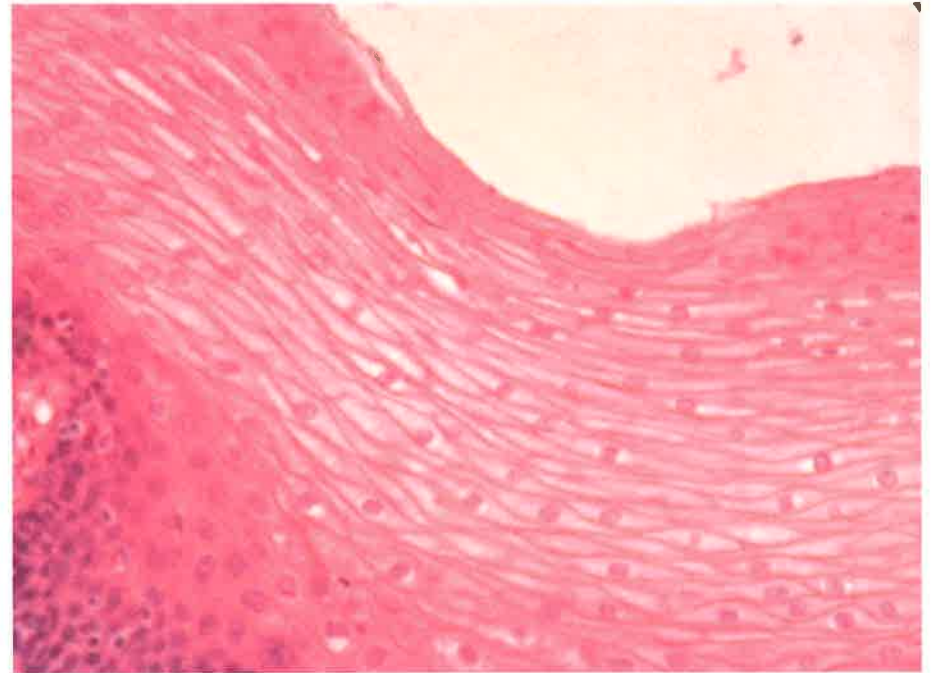
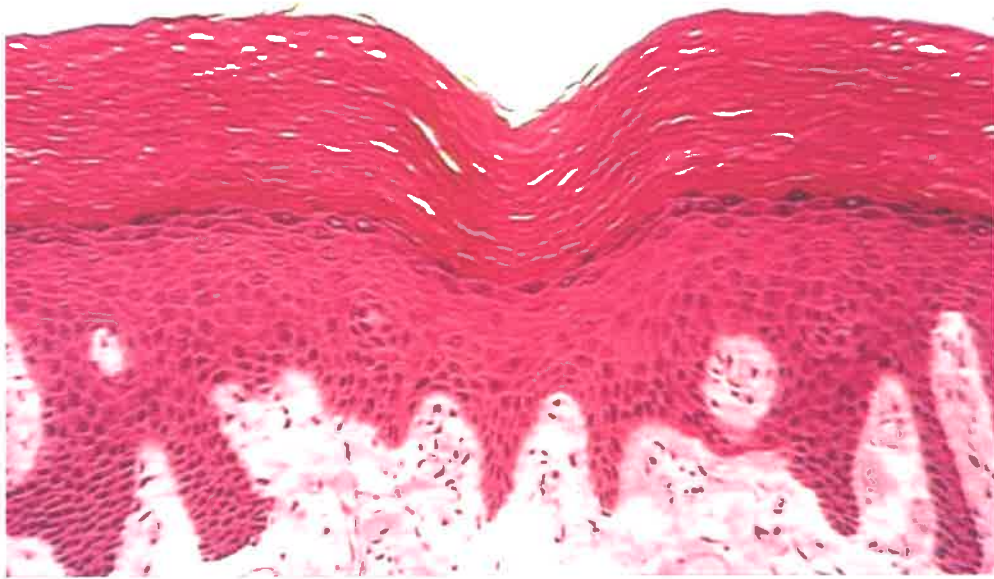


Ciliated Columnar

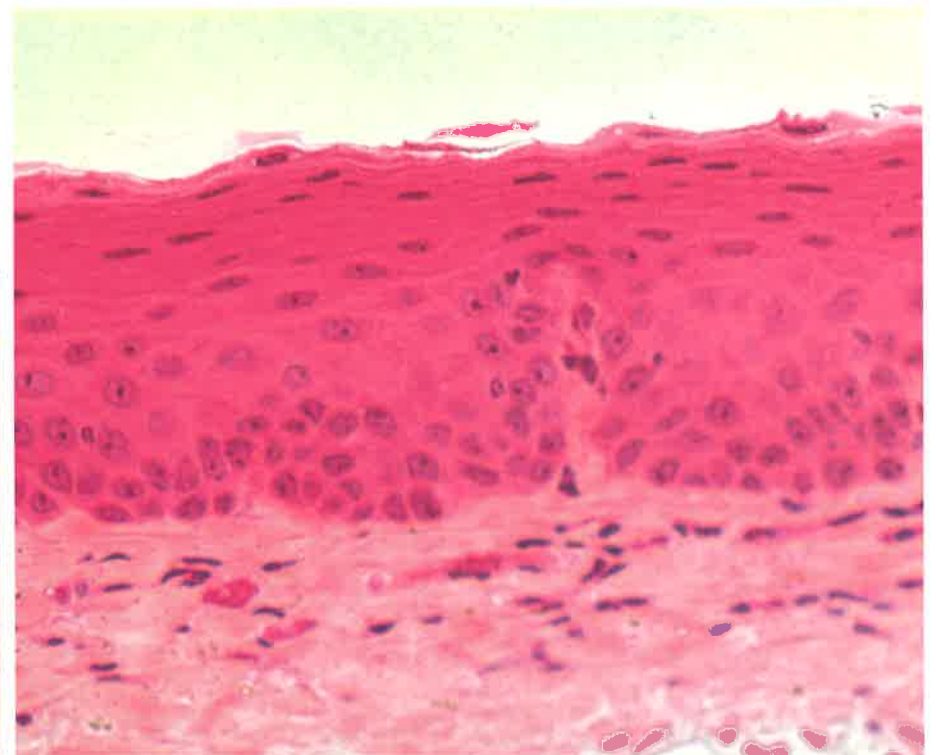
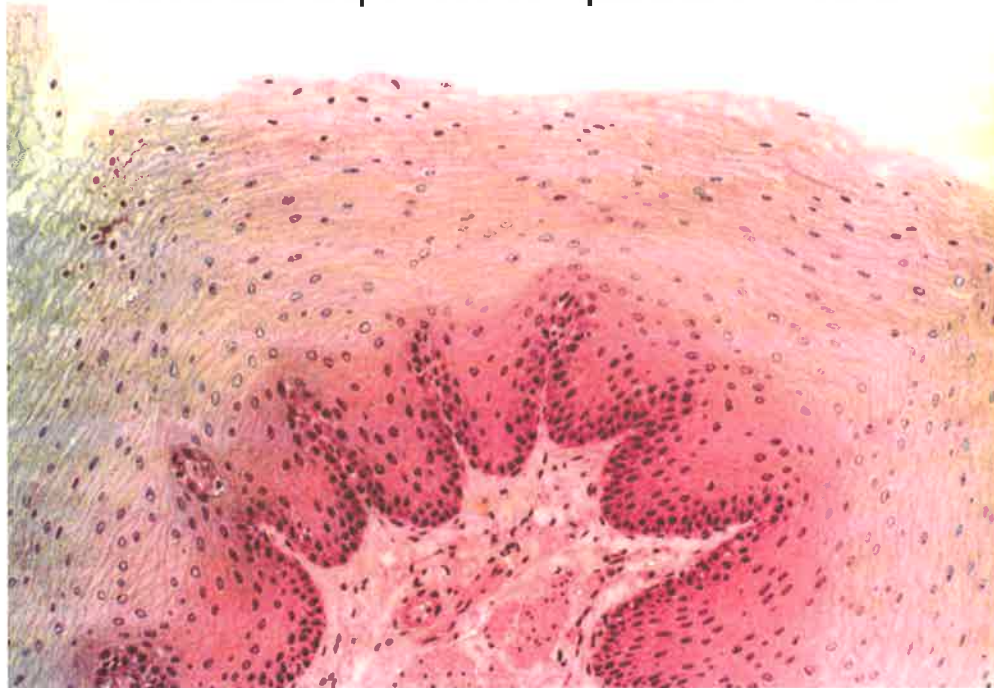


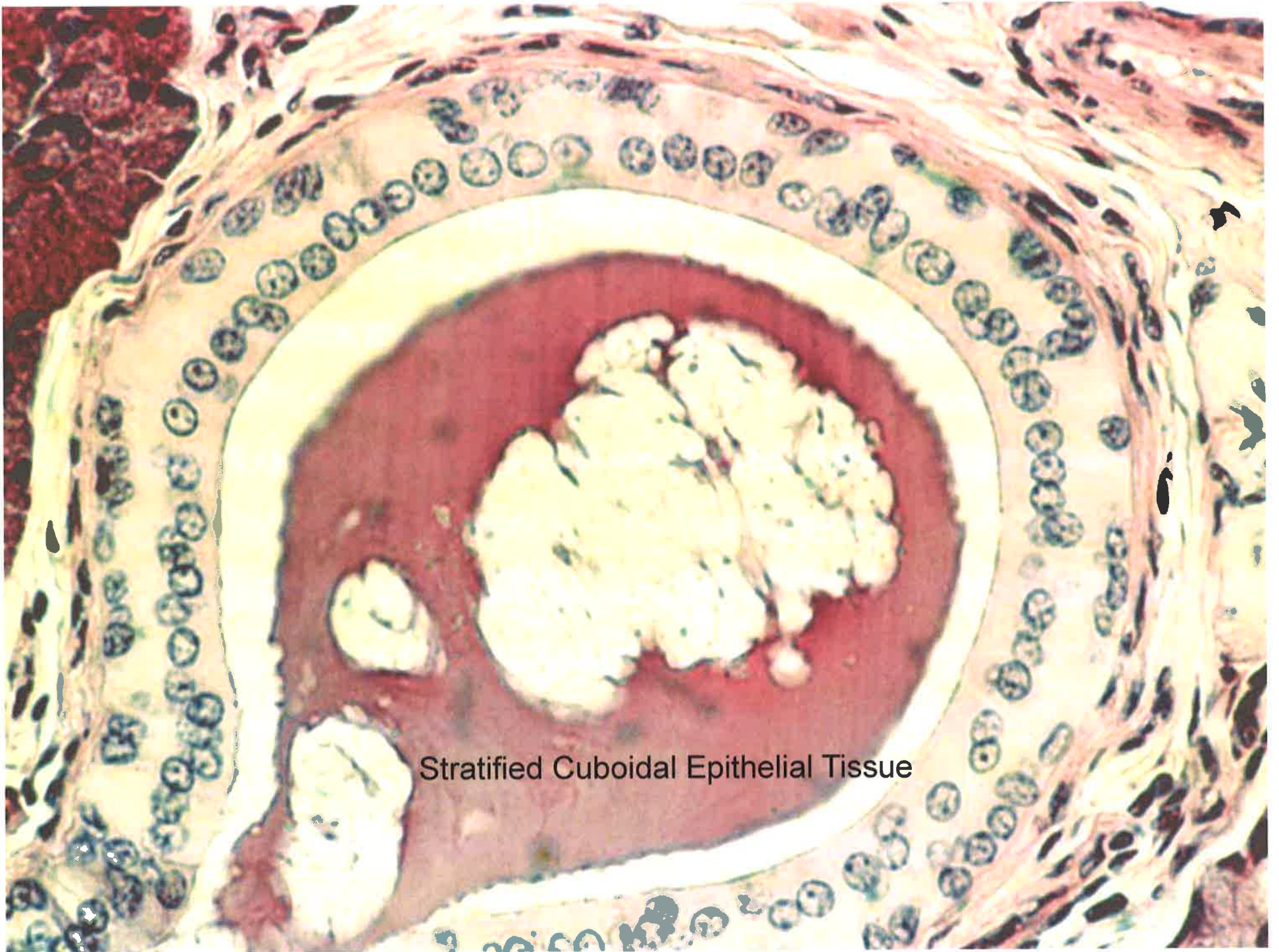
Pseudostratified Columnar Epithelial Tissue



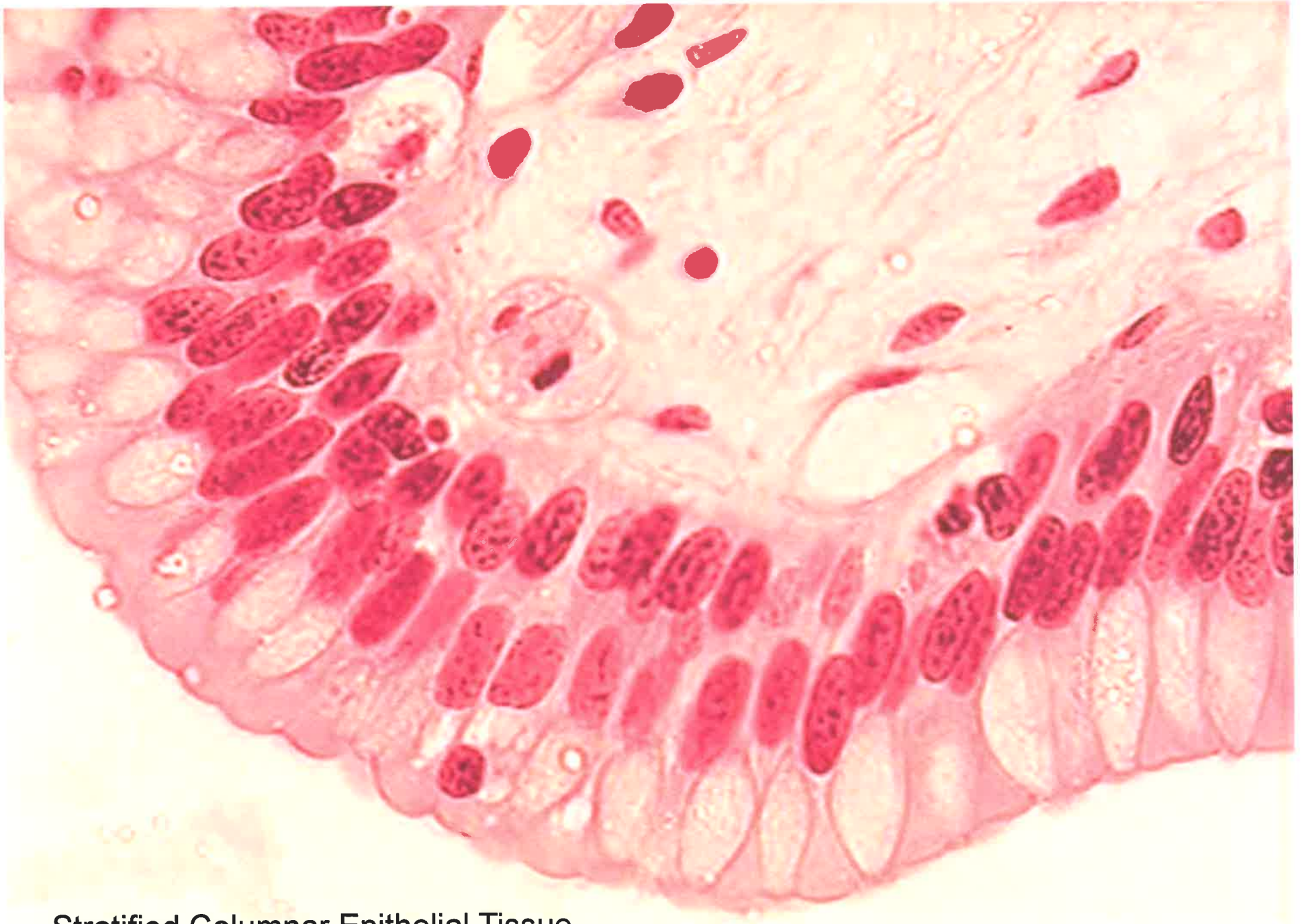

Stratified Squamous Epithelial Tissue

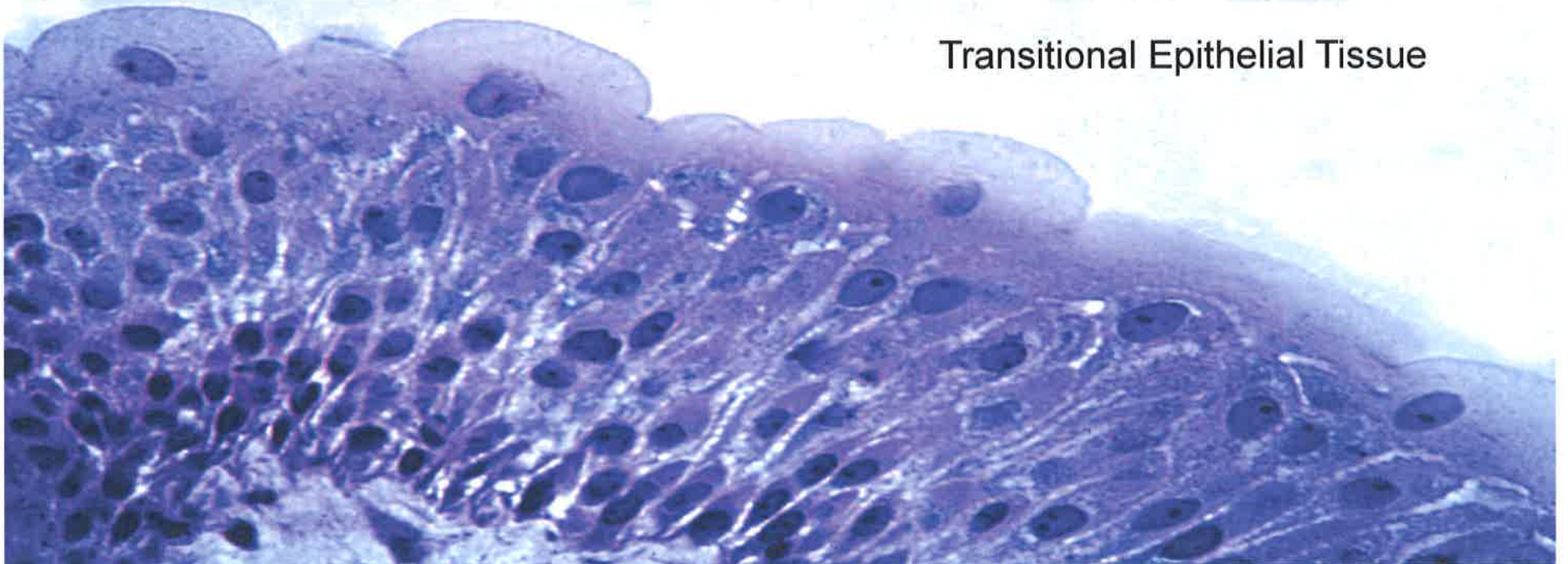
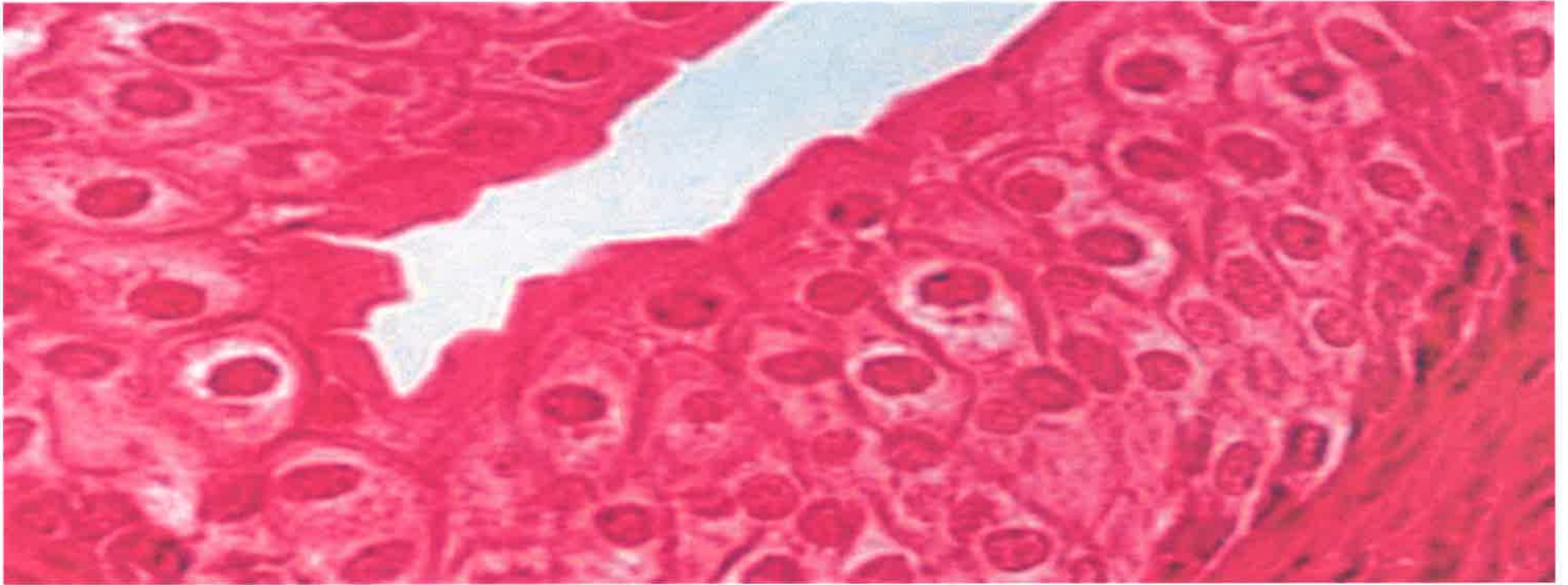



Stratified Cuboidal Epithelial Tissue

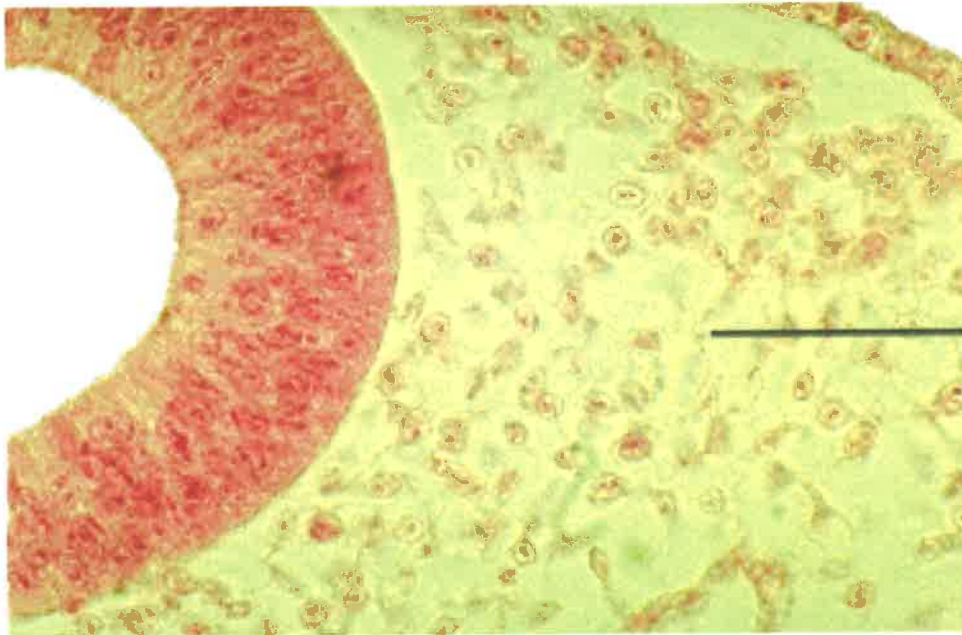
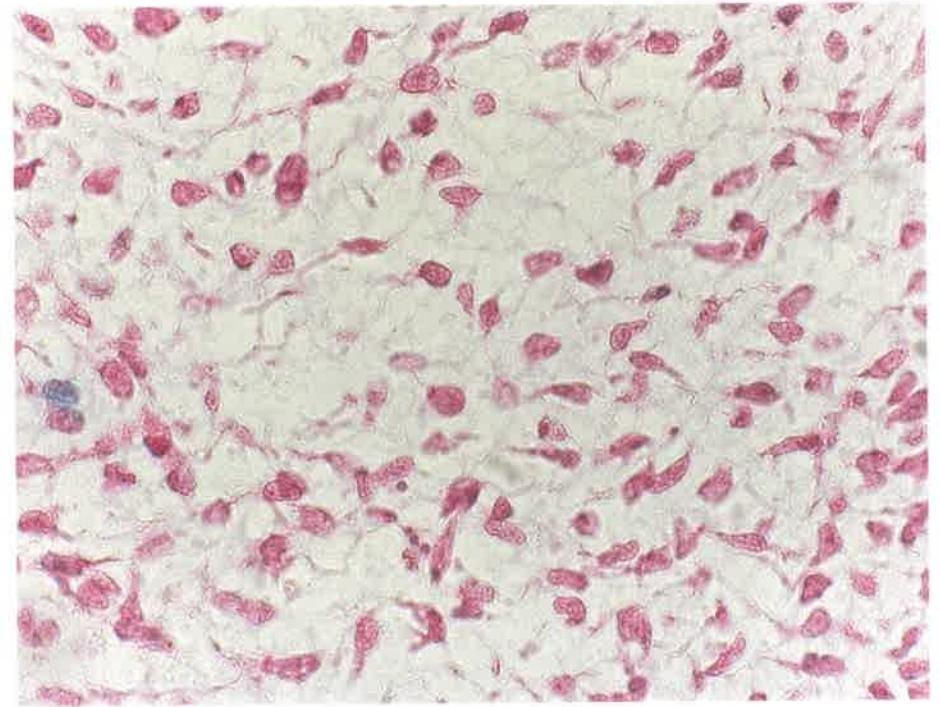


Stratified Columnar Epithelial Tissue

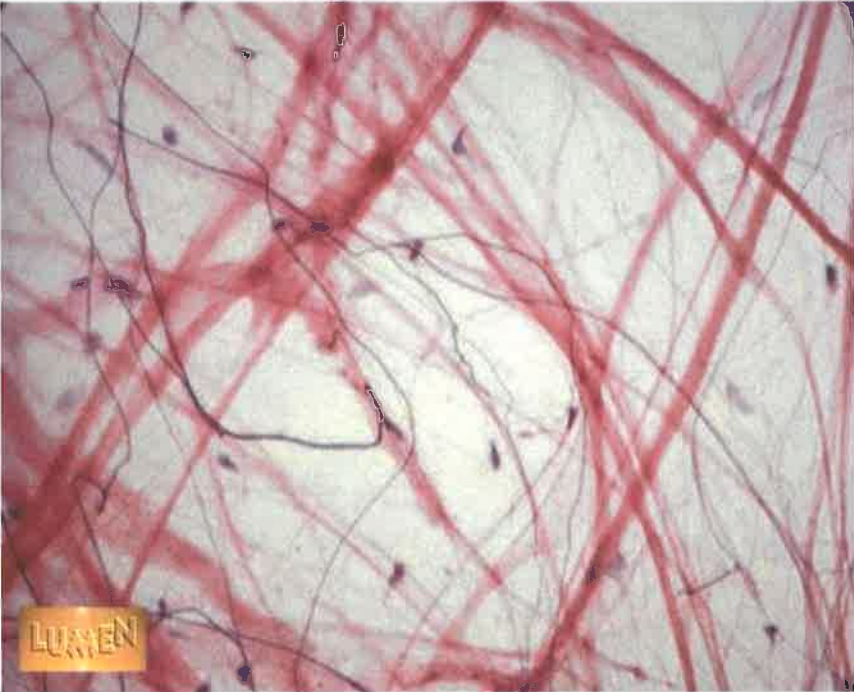
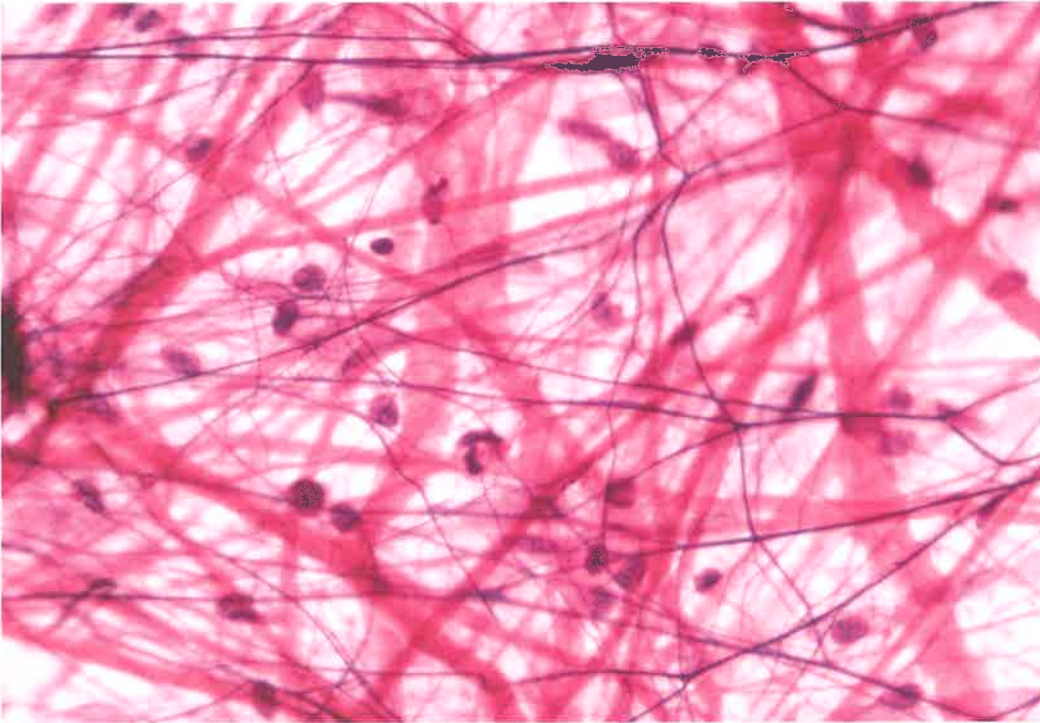


Transitional Epithelial Tissue

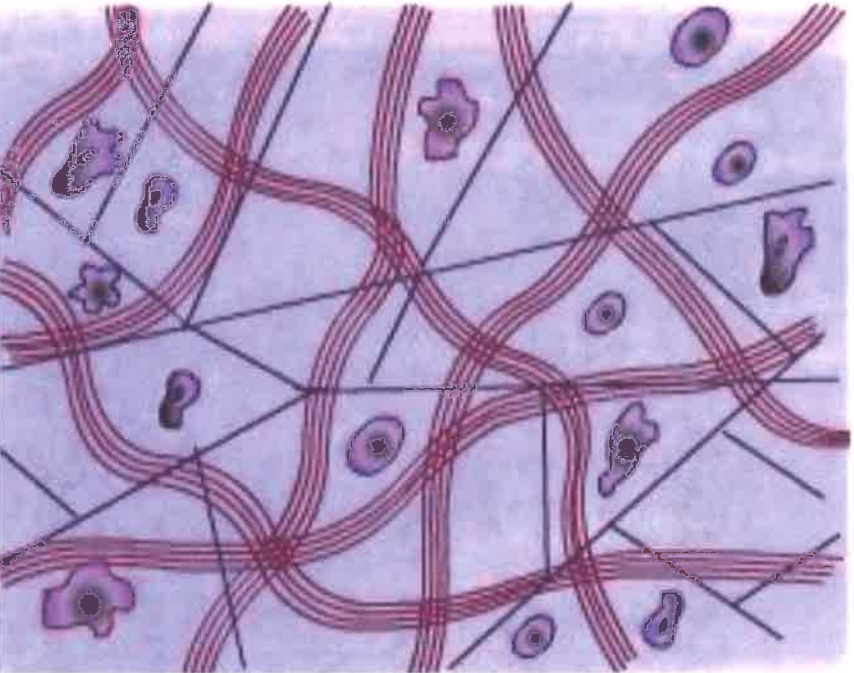
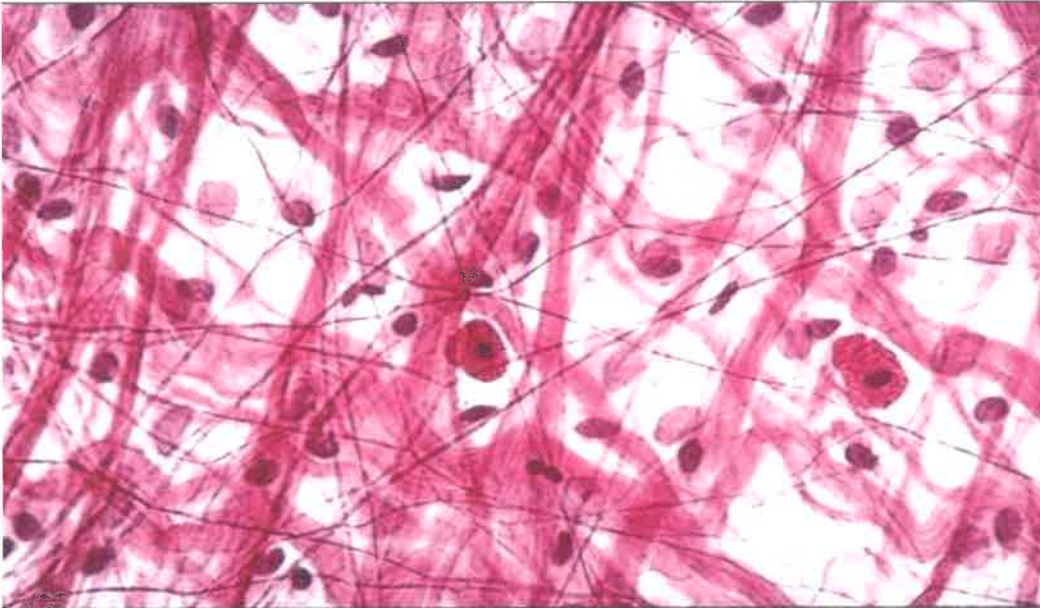
Mesenchyme – Embryonic Connective Tissue

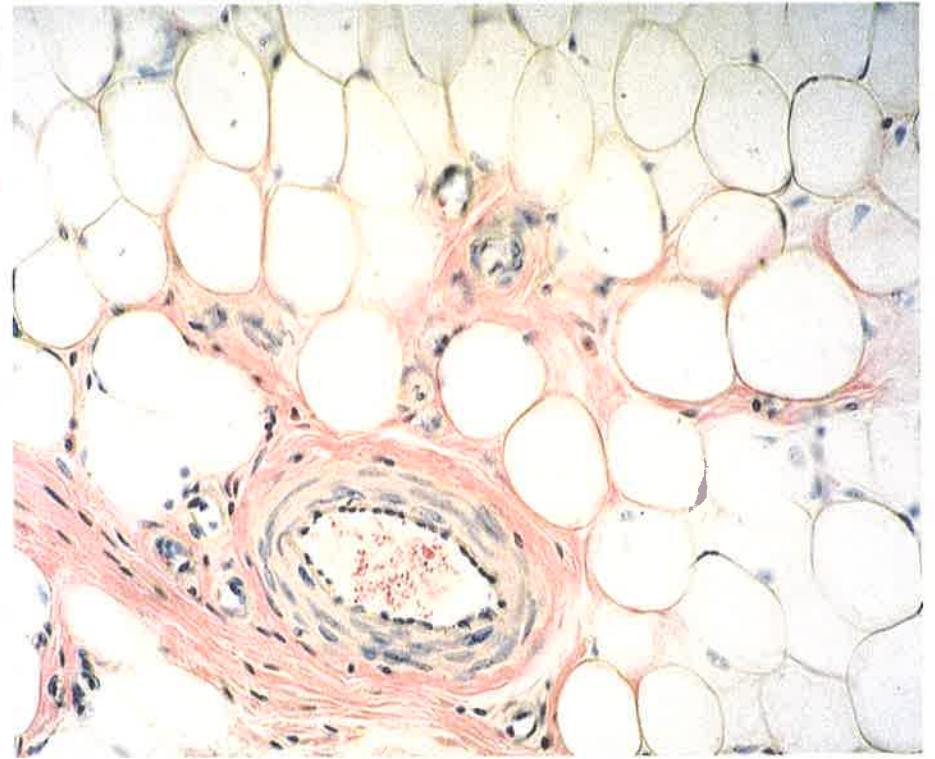
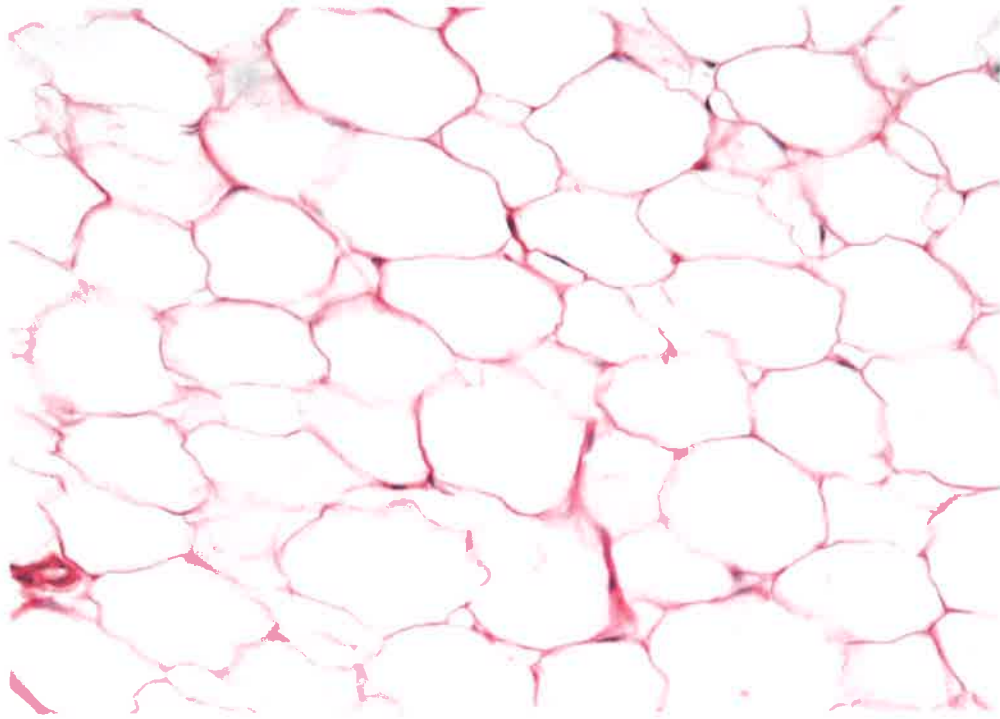


| Mucus – from umbilical cord

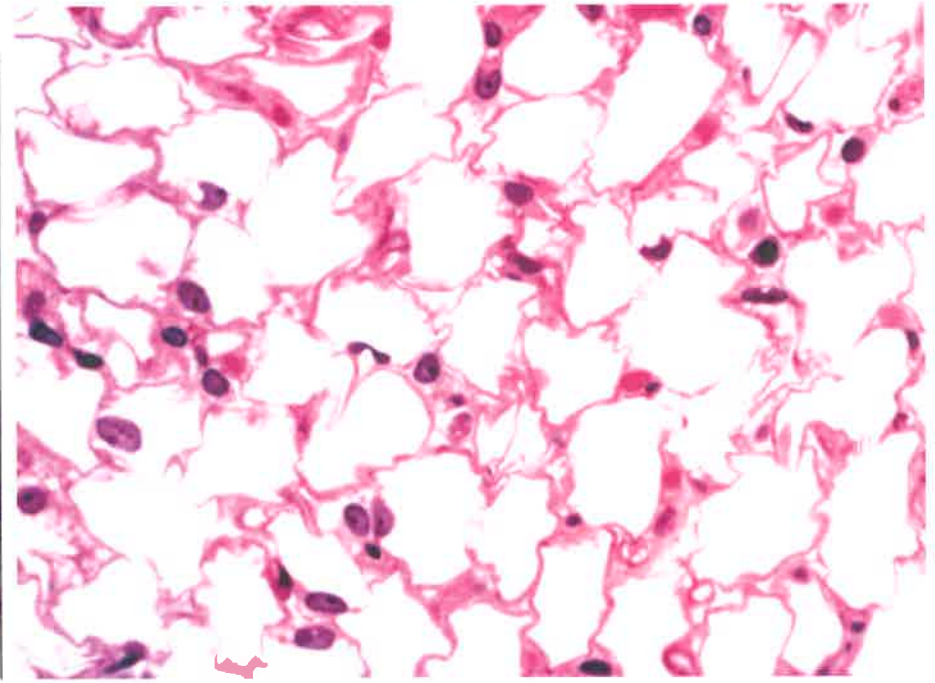
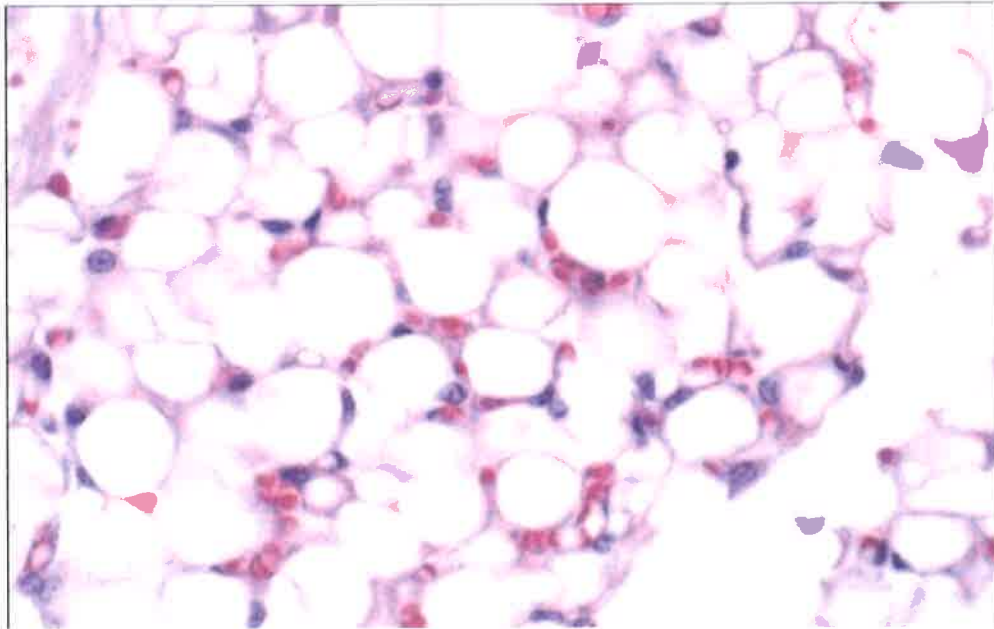


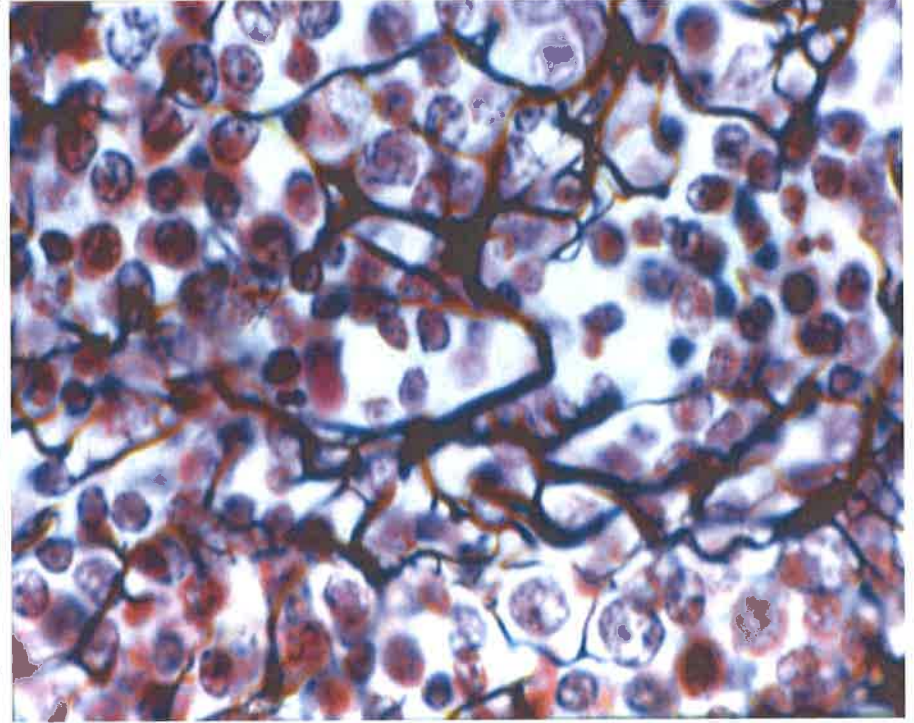
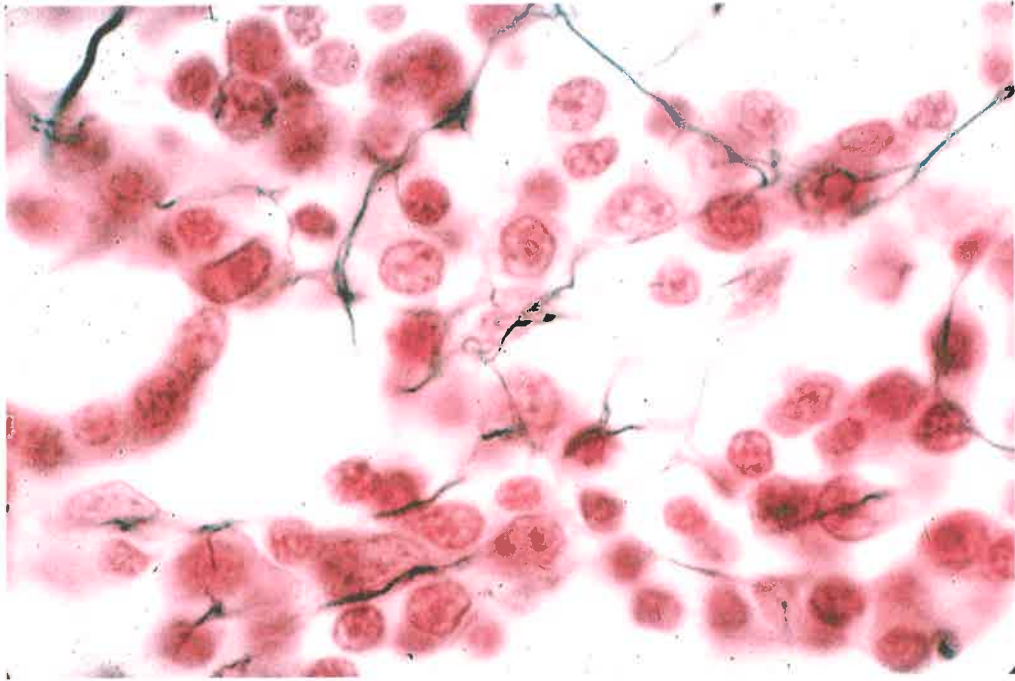
Areolar Tissue – Loose connective



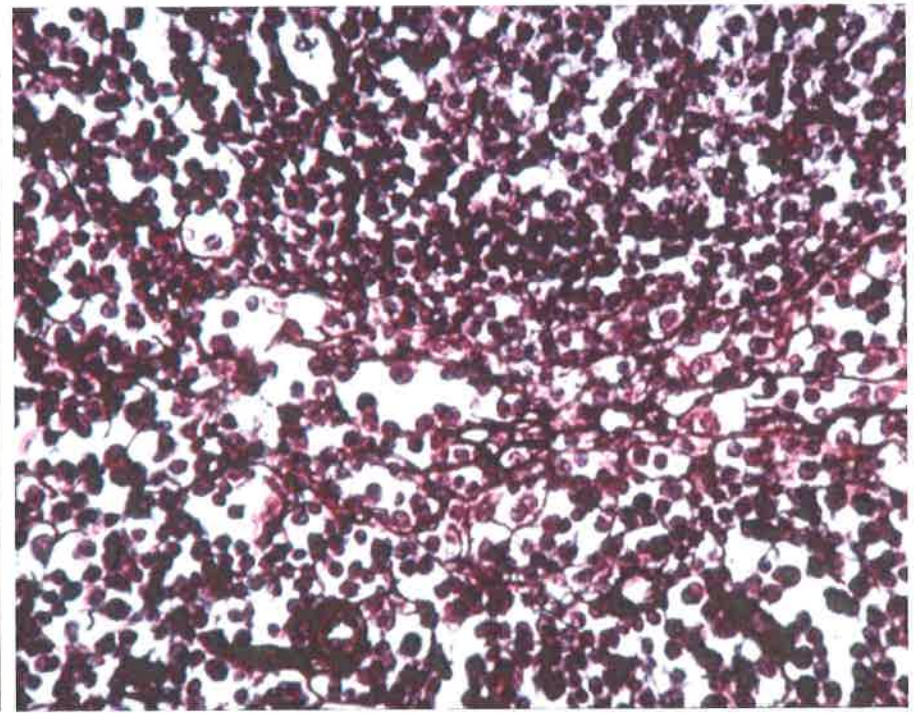
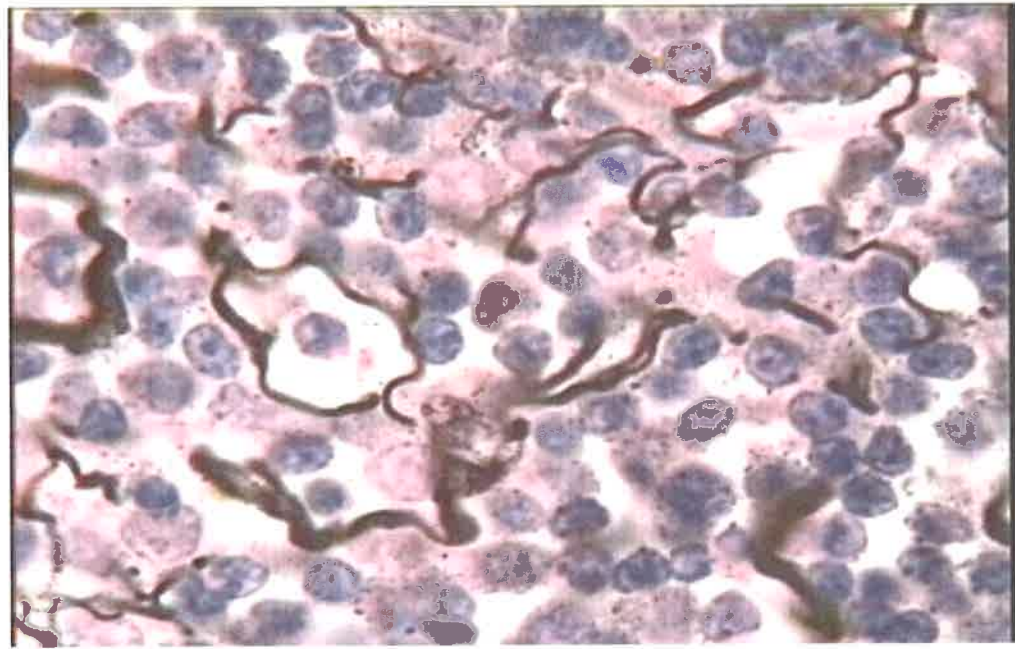


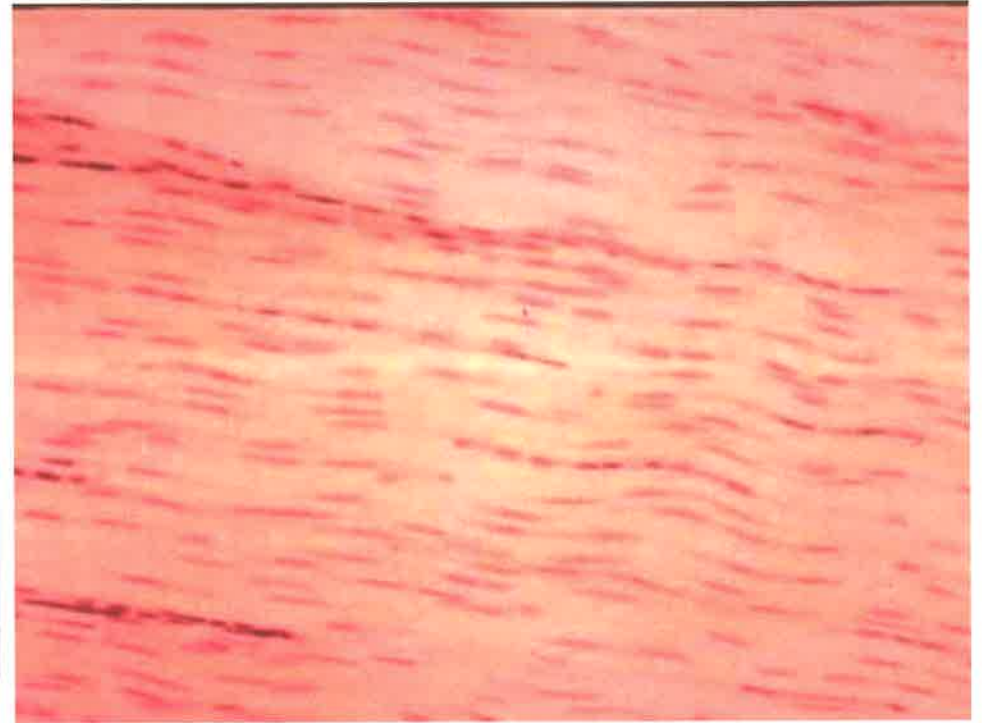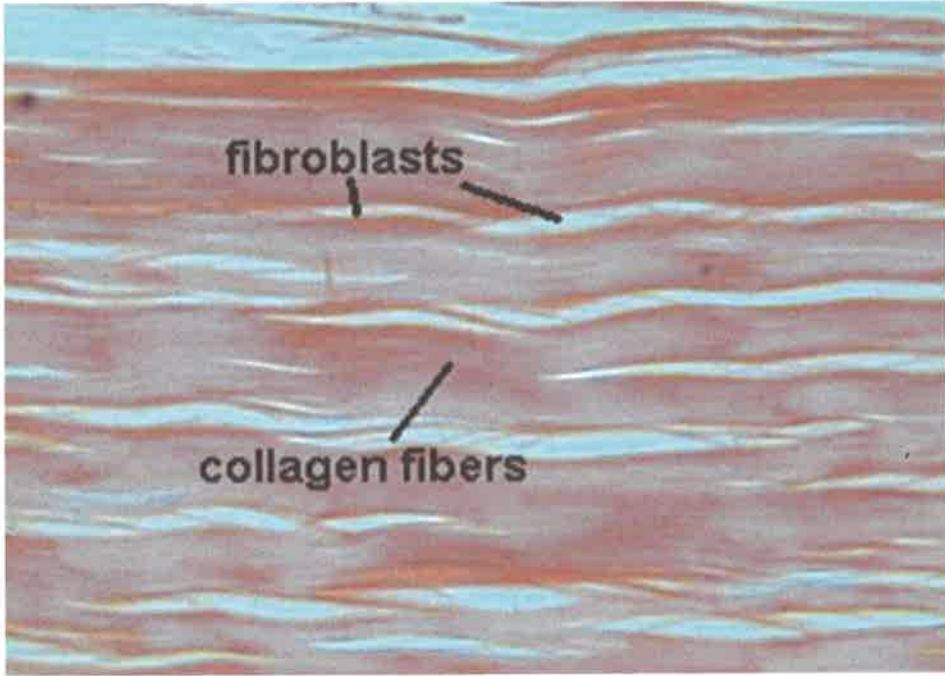
Adipose Tissue – Loose connective



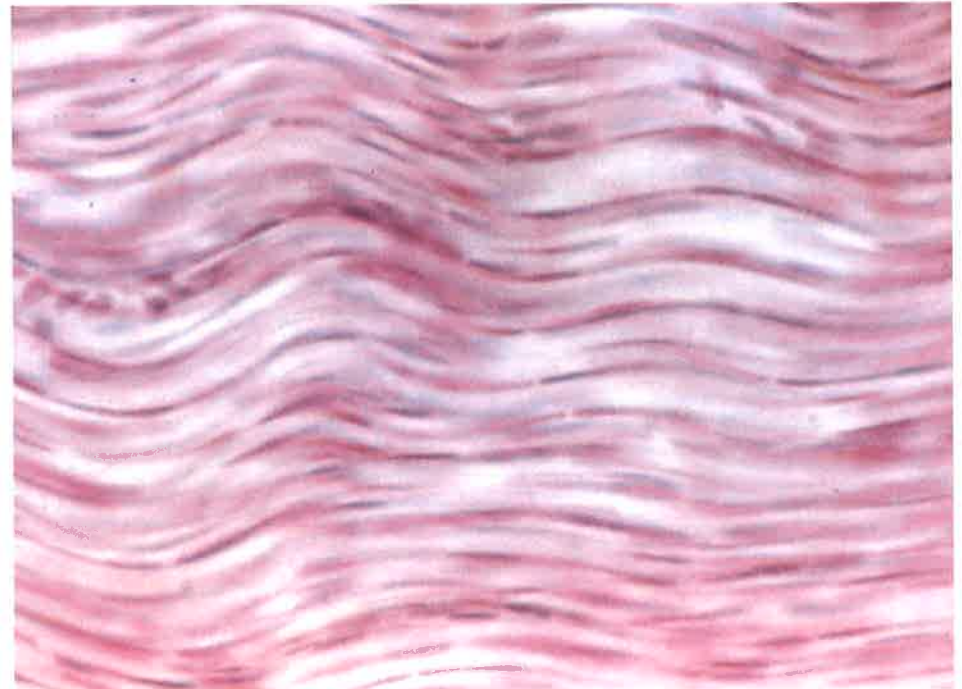


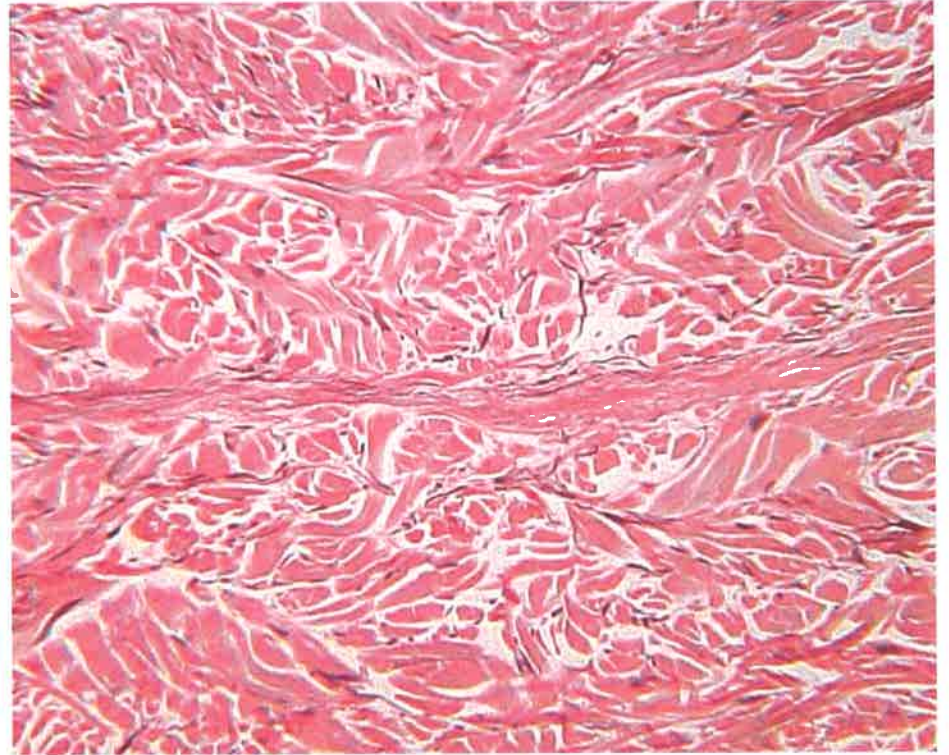
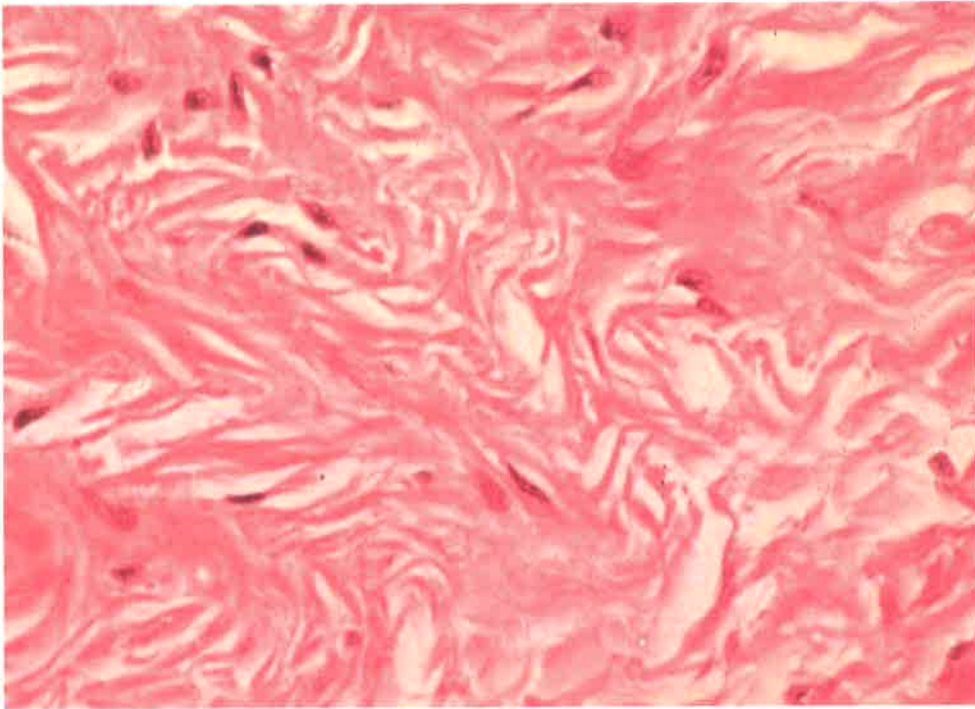
Reticular Tissue – Loose connective



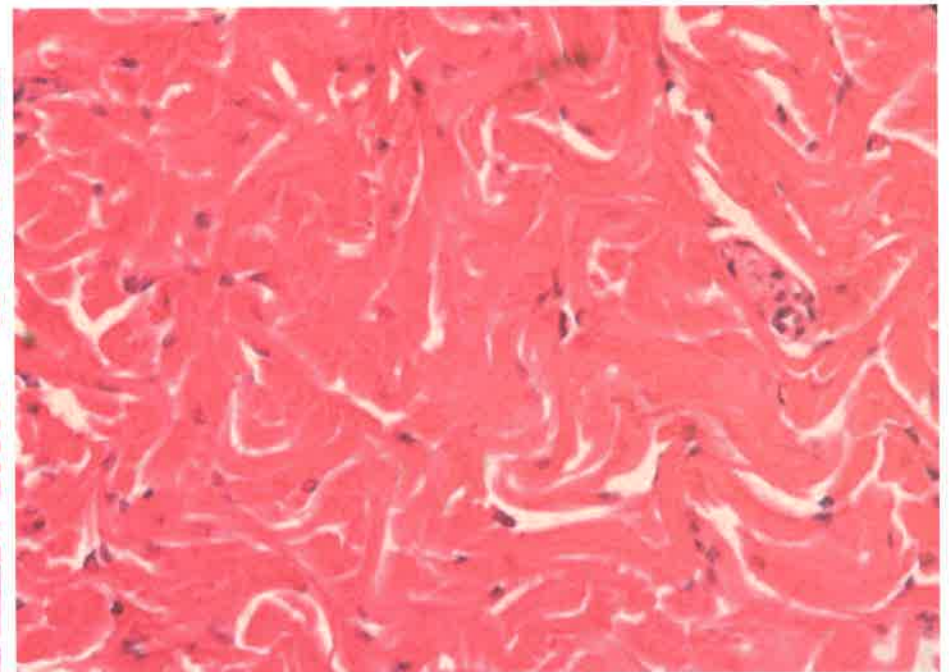
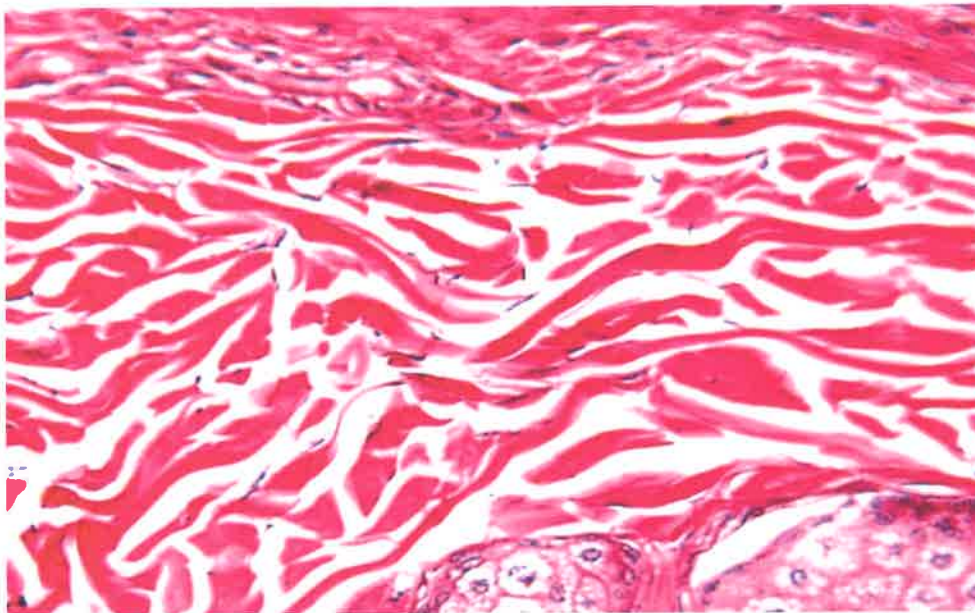


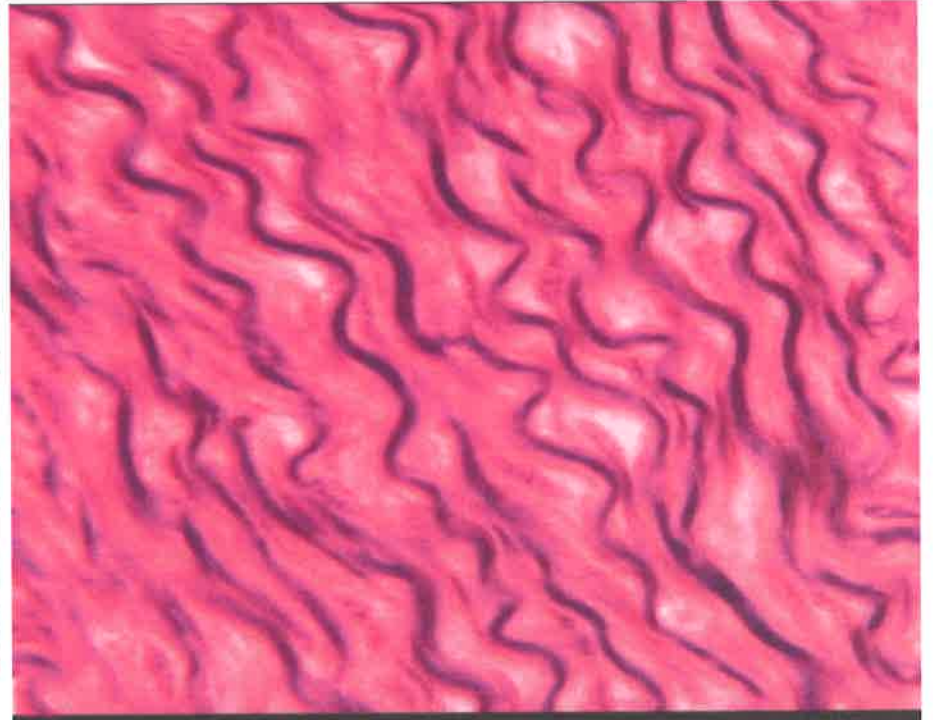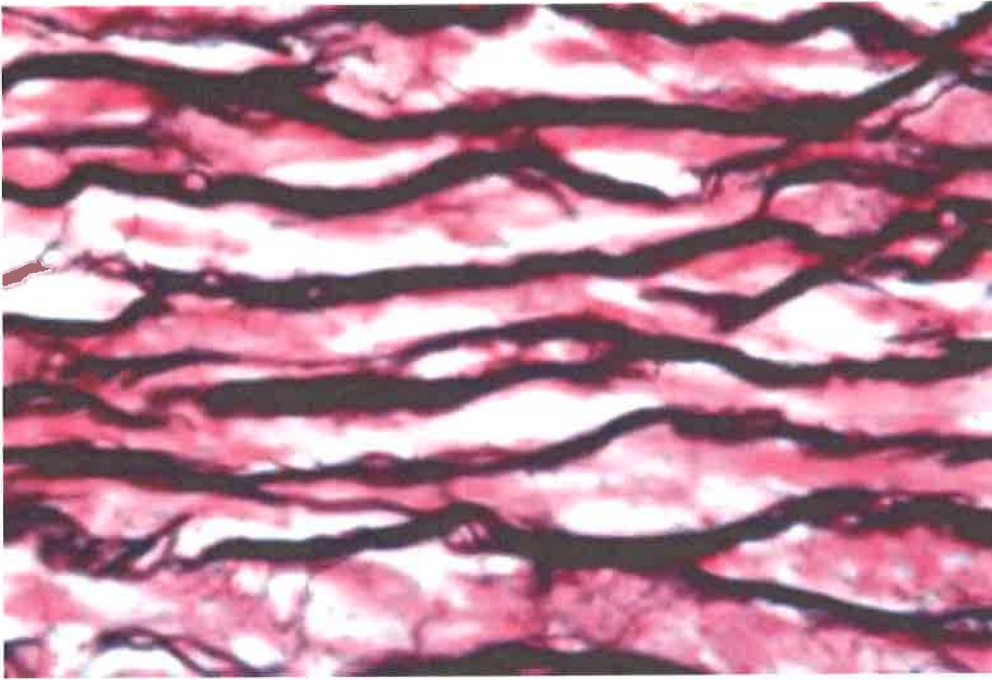
Dense Regular Connective Tissue



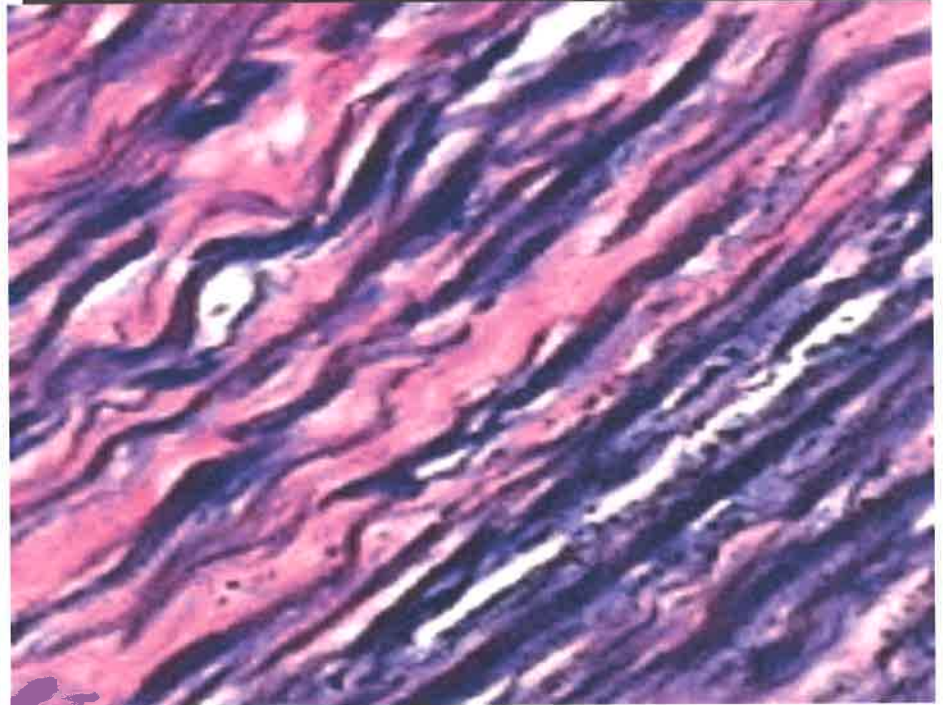
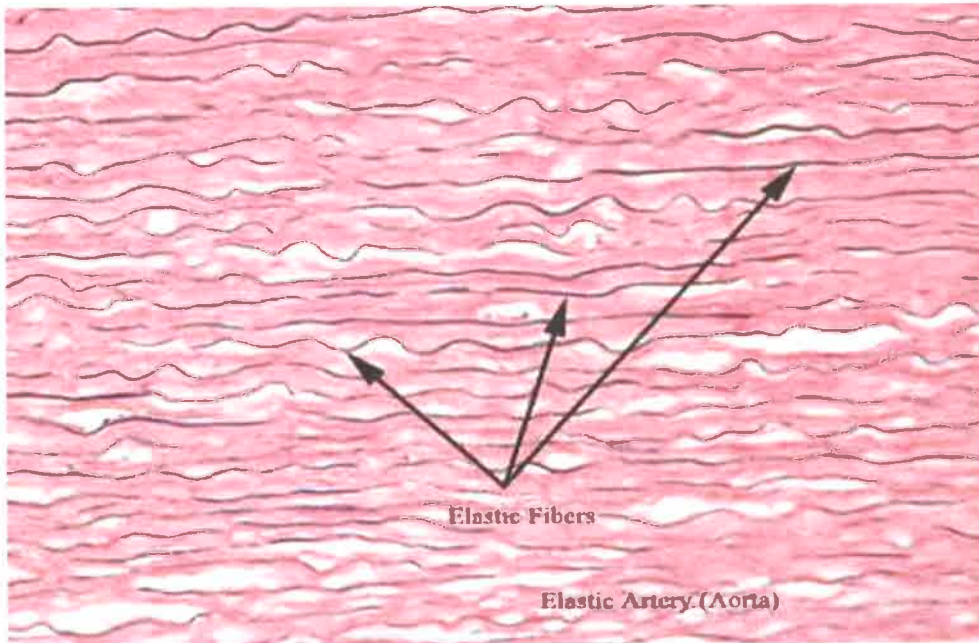


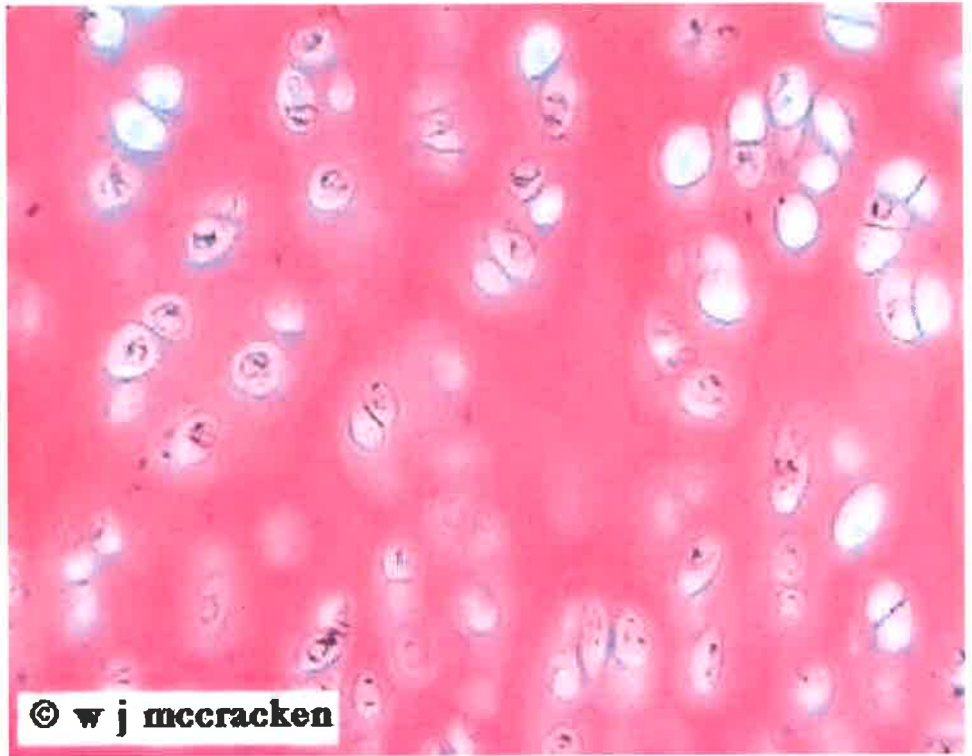
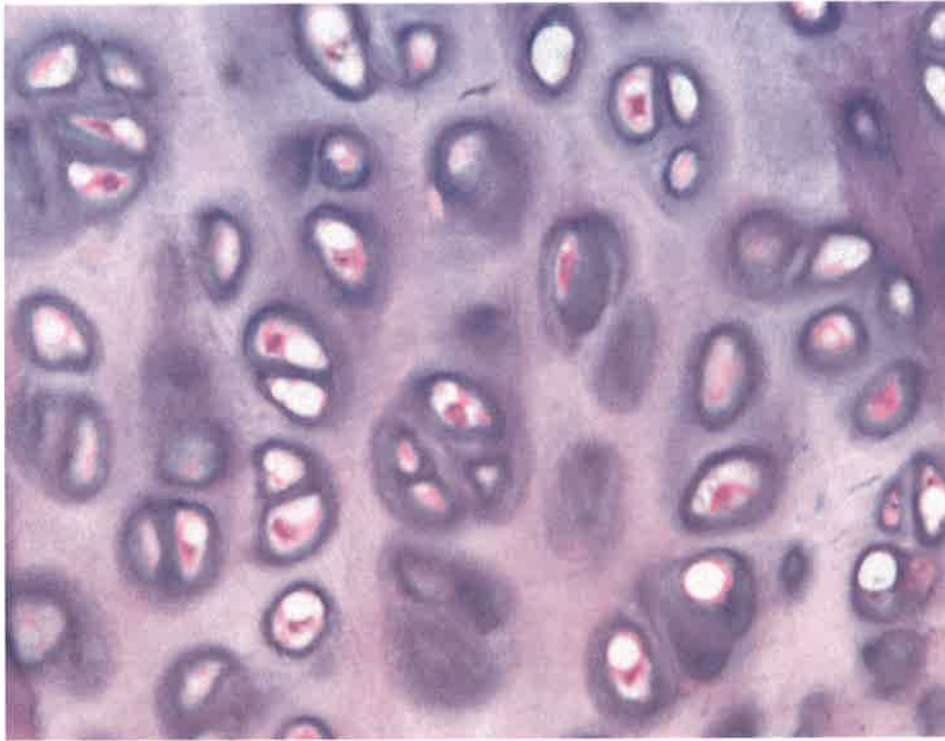
Dense Irregular Connective Tissue



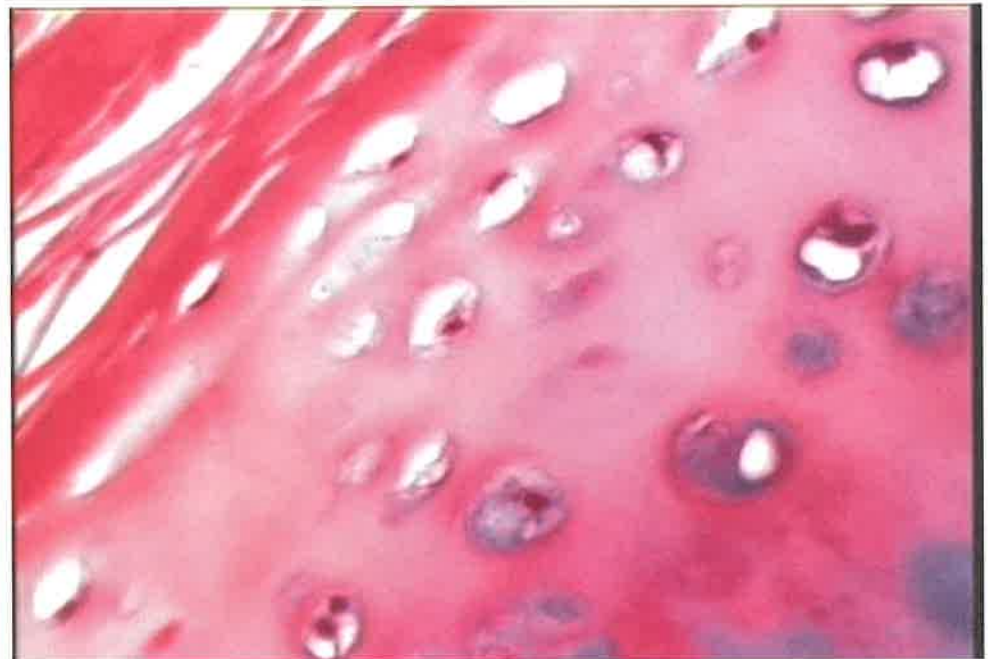
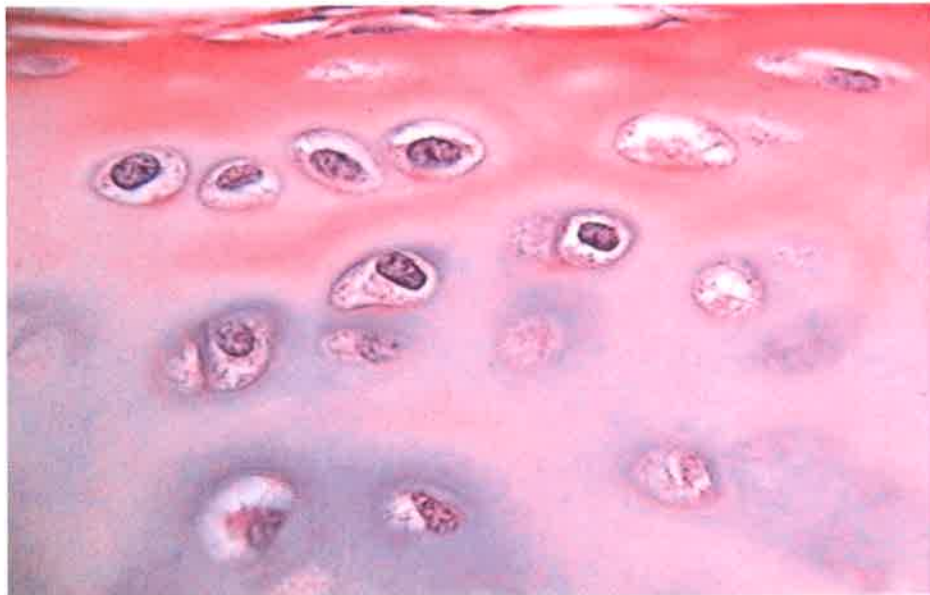


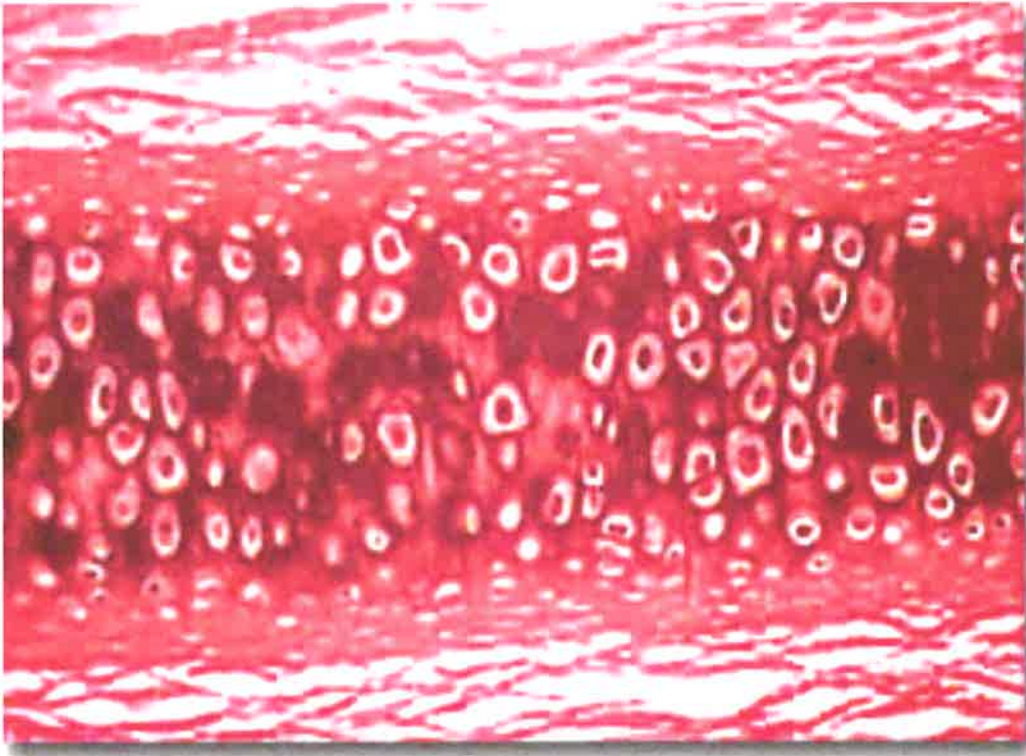
Elastic Connective Tissue



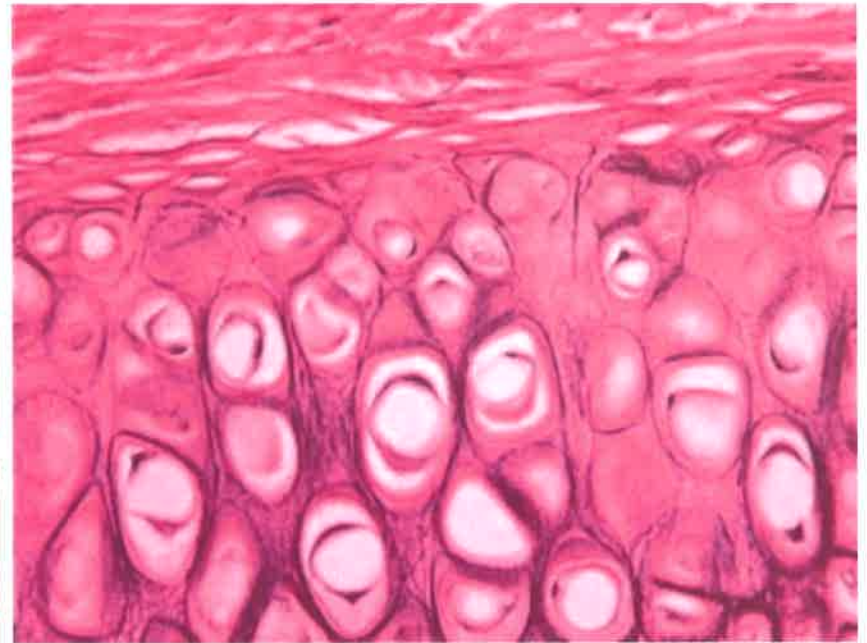
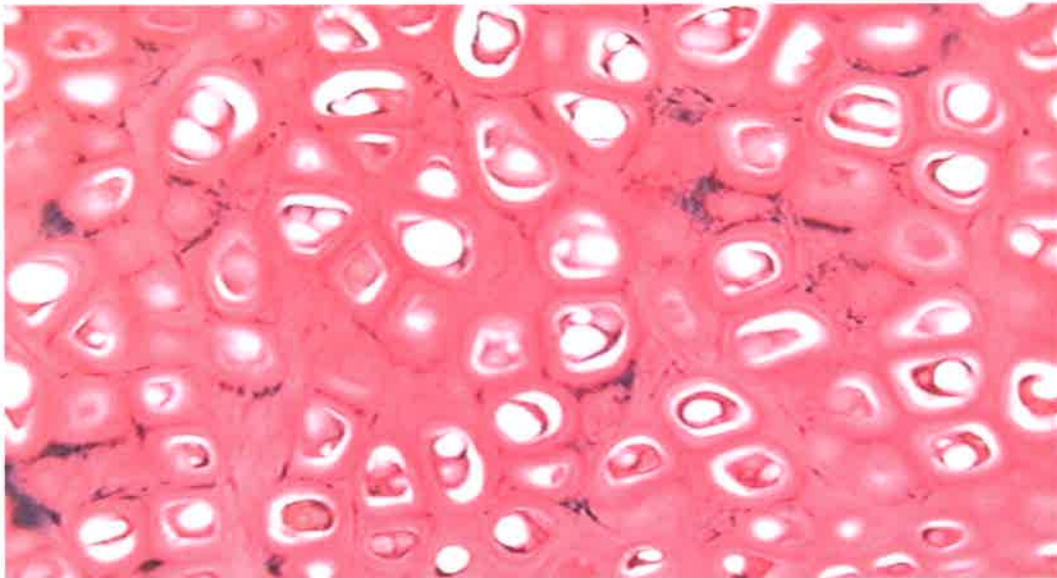
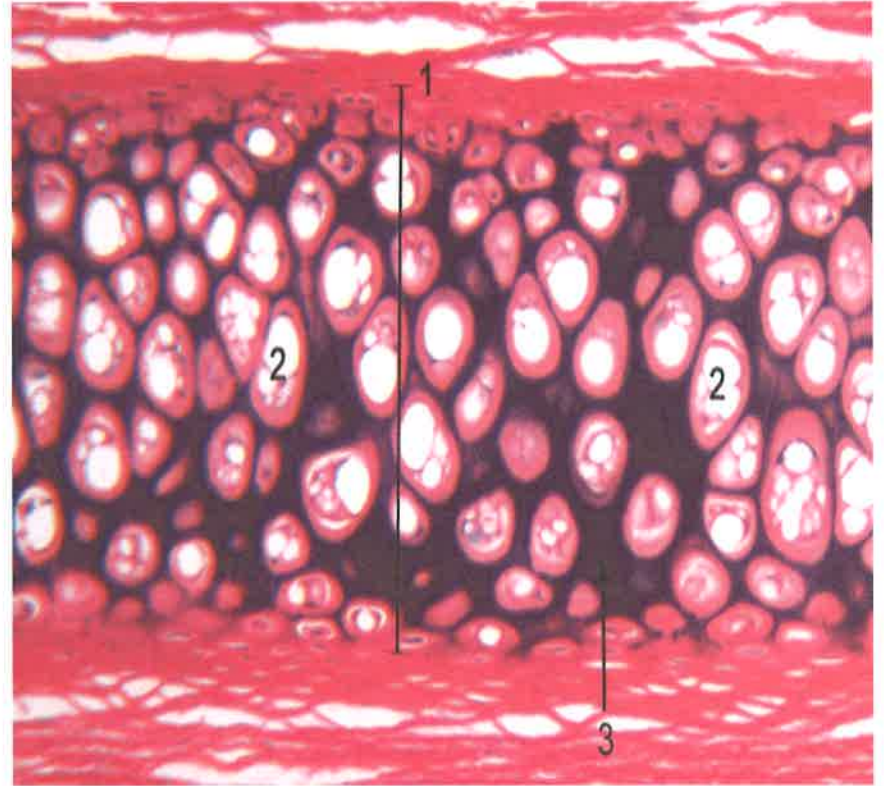


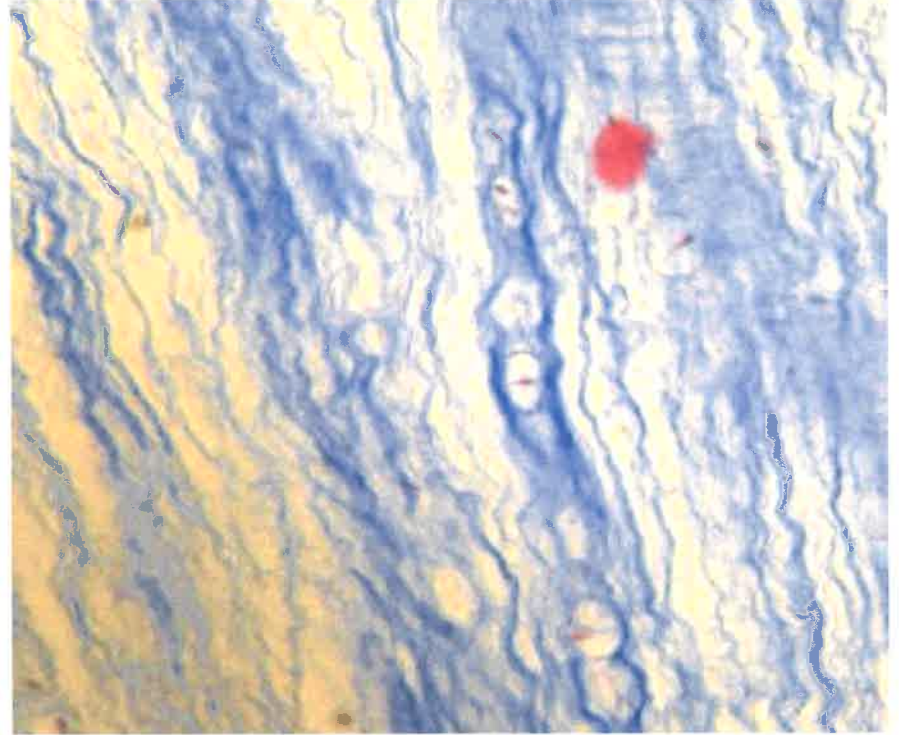
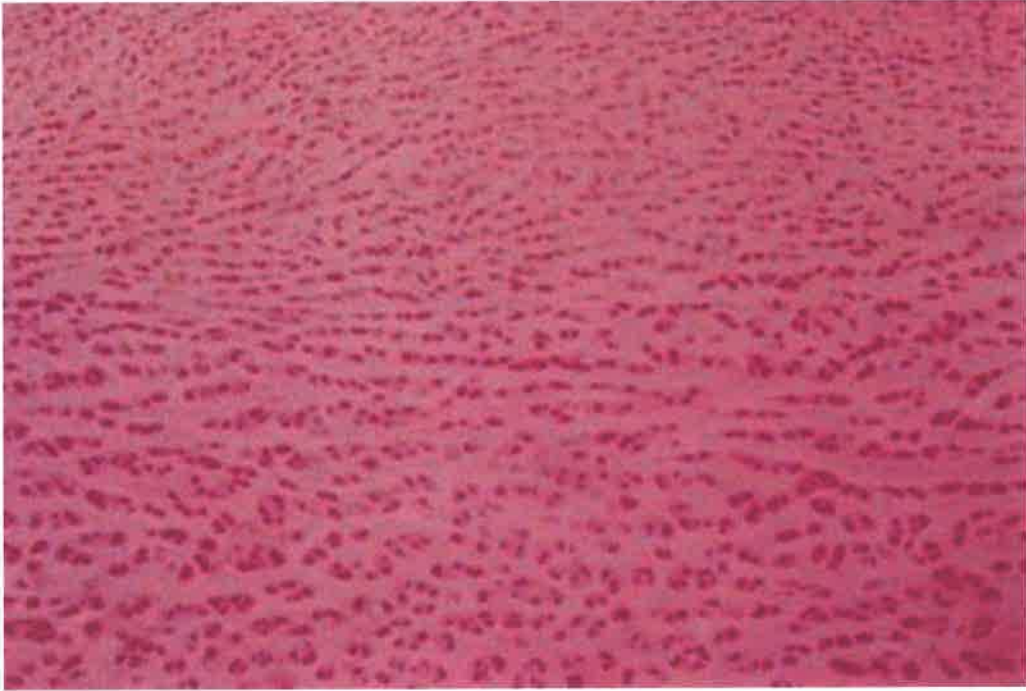
Hyaline cartilage



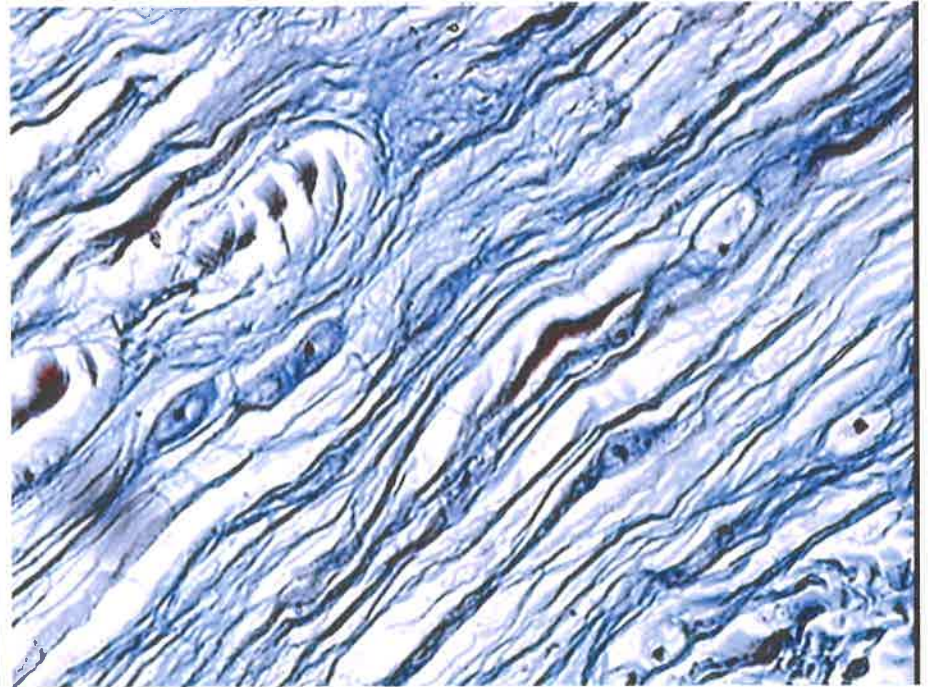
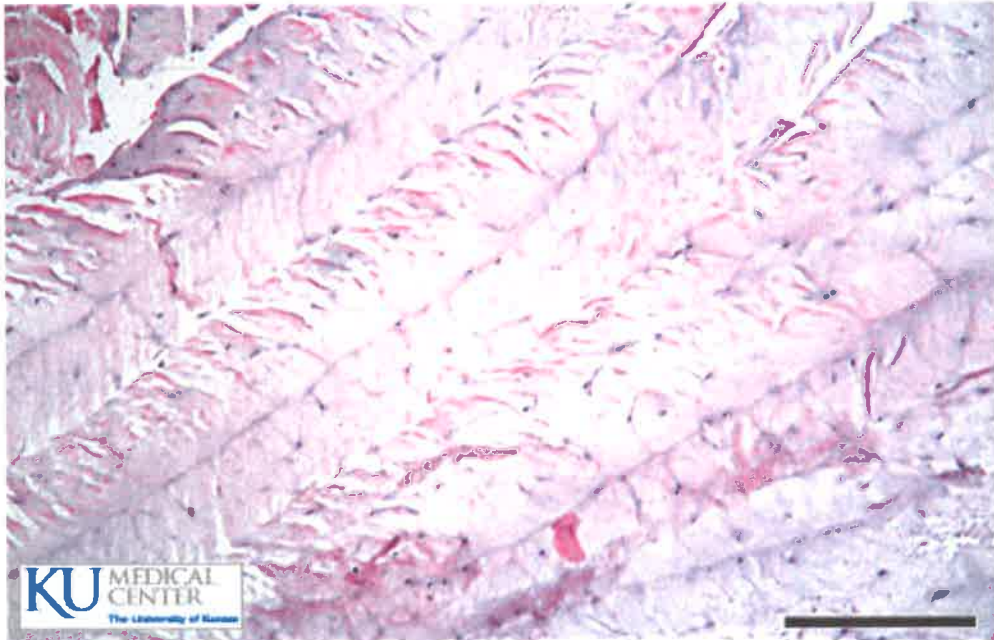


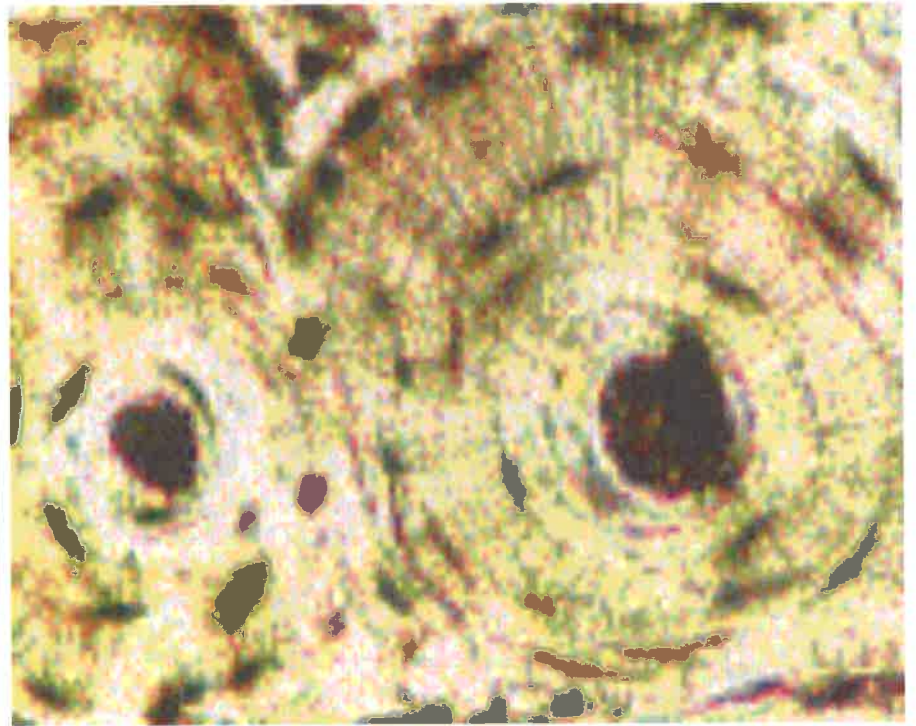
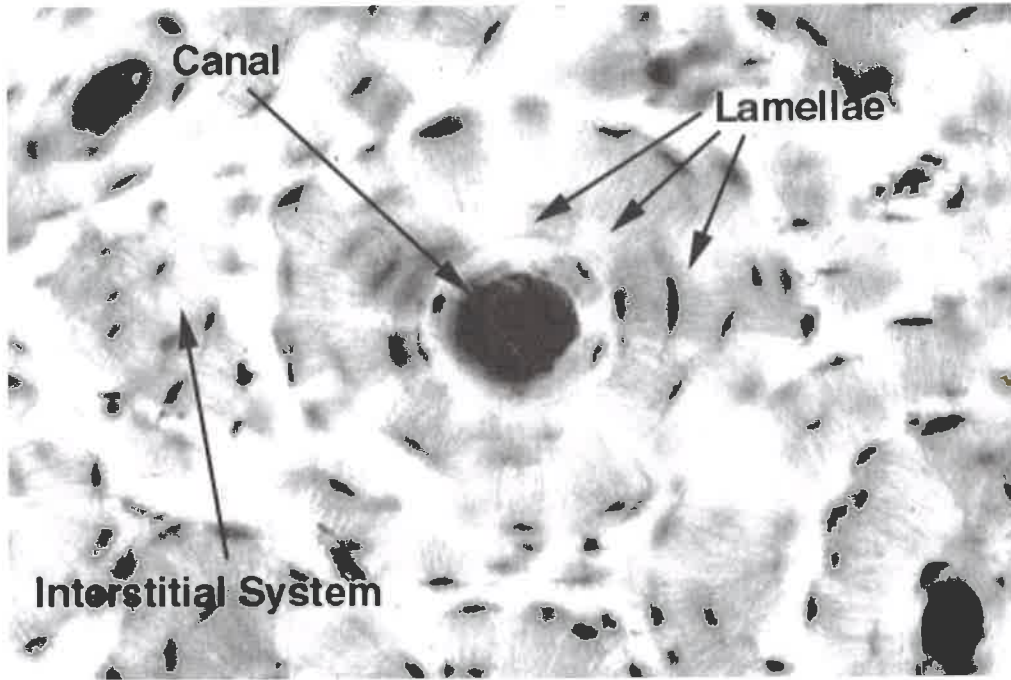
Elastic cartilage



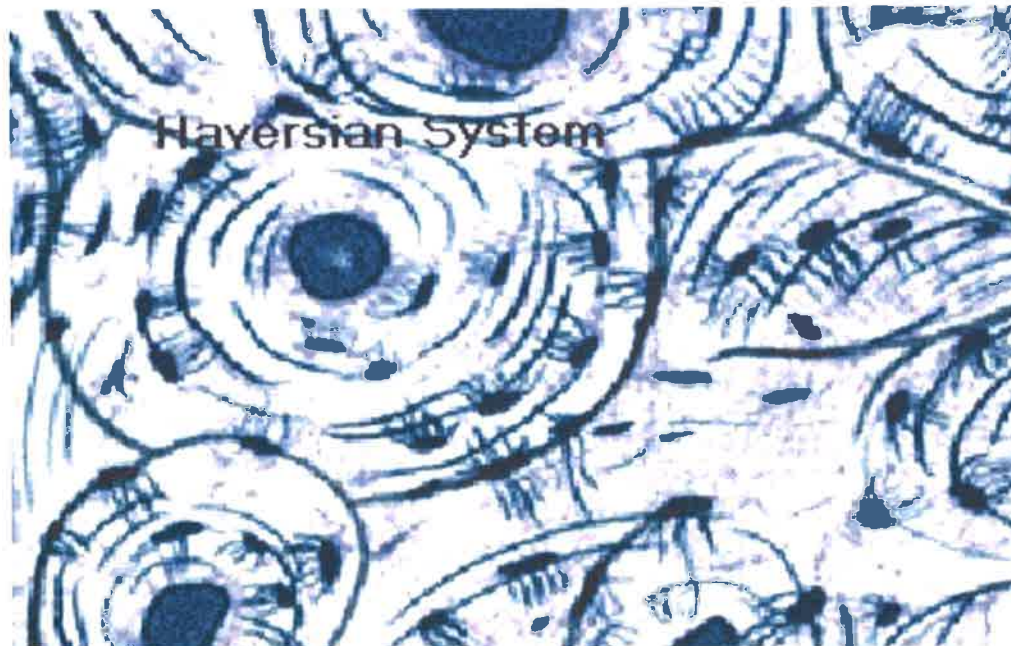


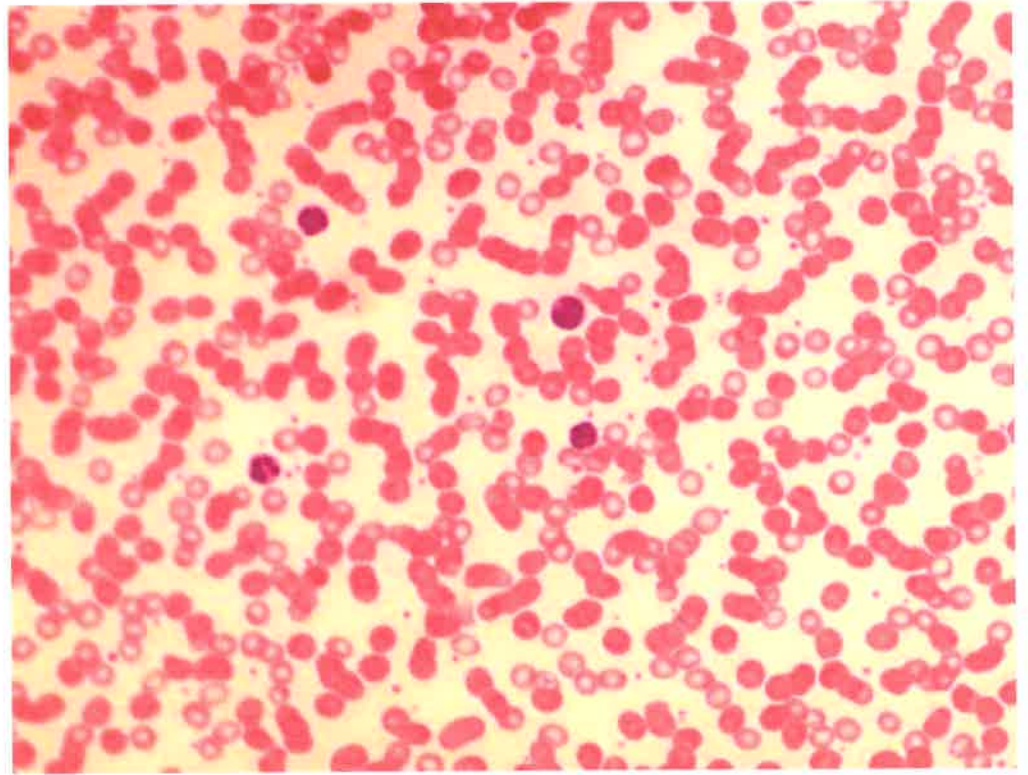
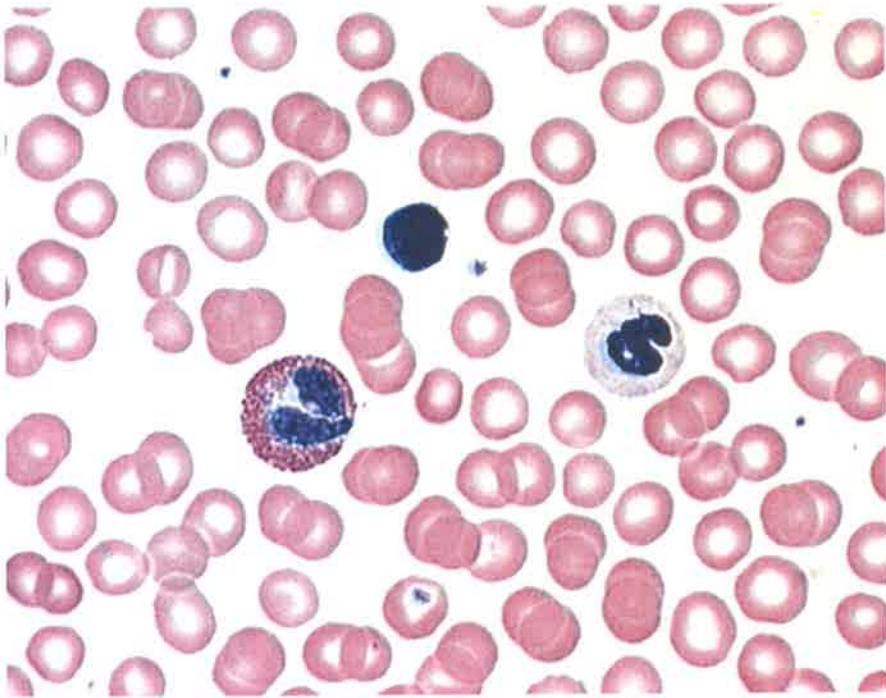
Fibro cartilage



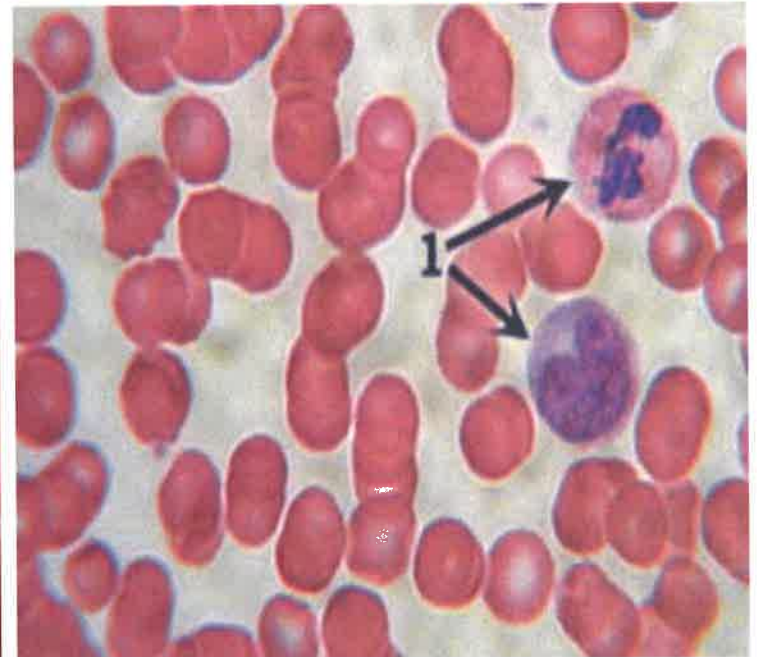
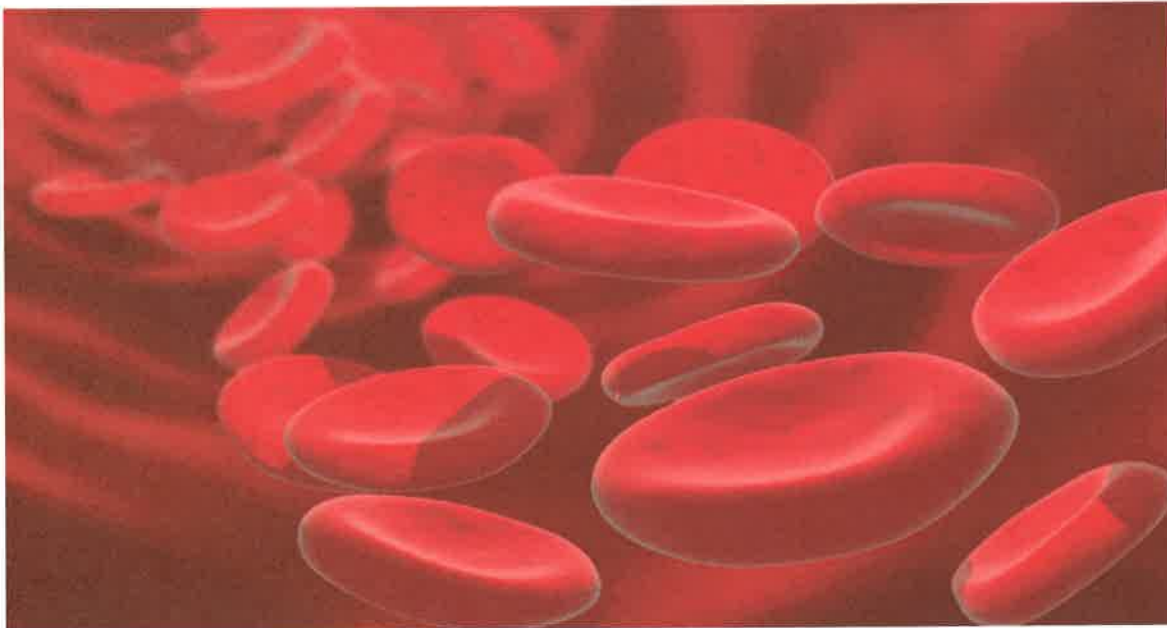


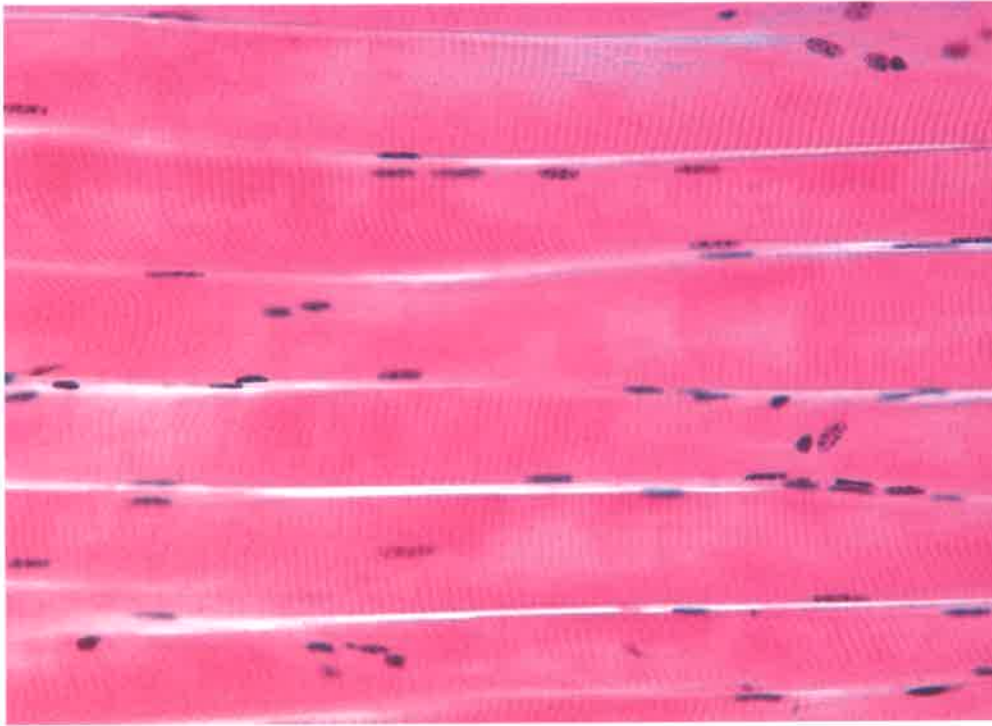
Osseous Tissue - Bone





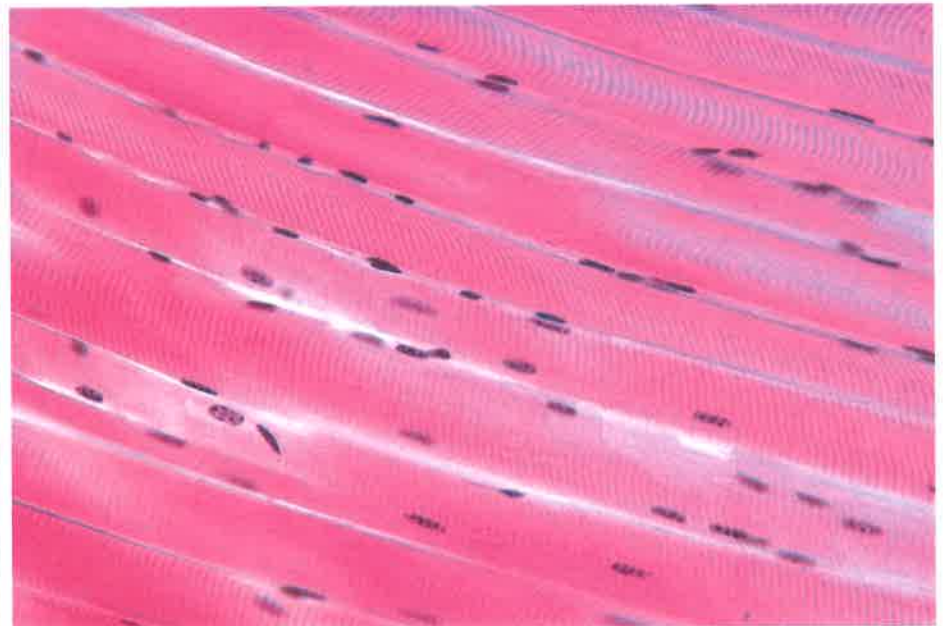

Blood – Fluid connective tissue

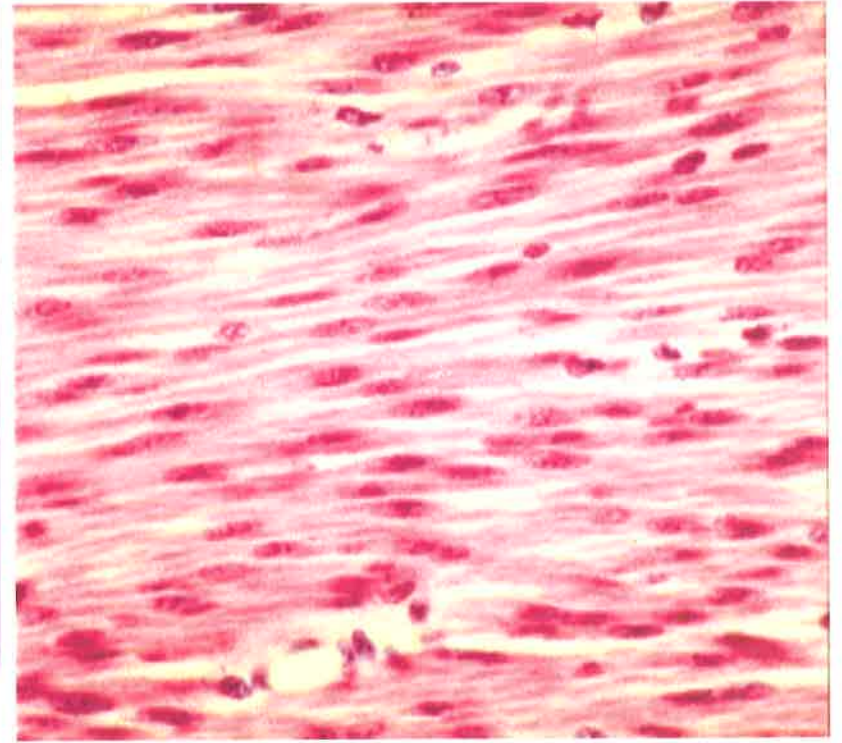
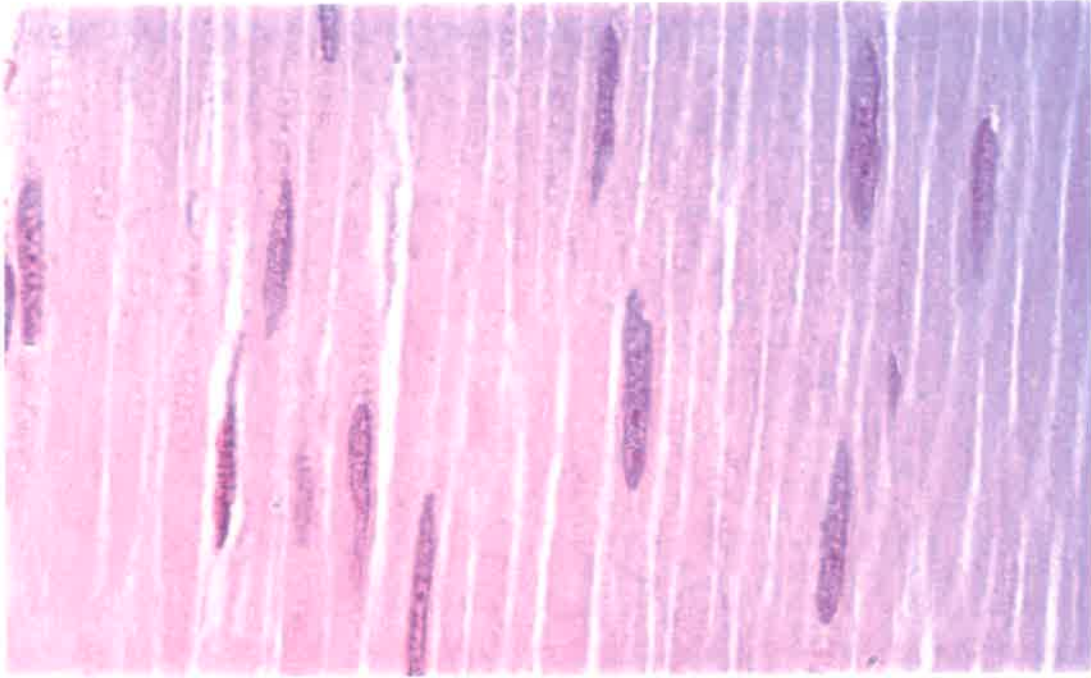




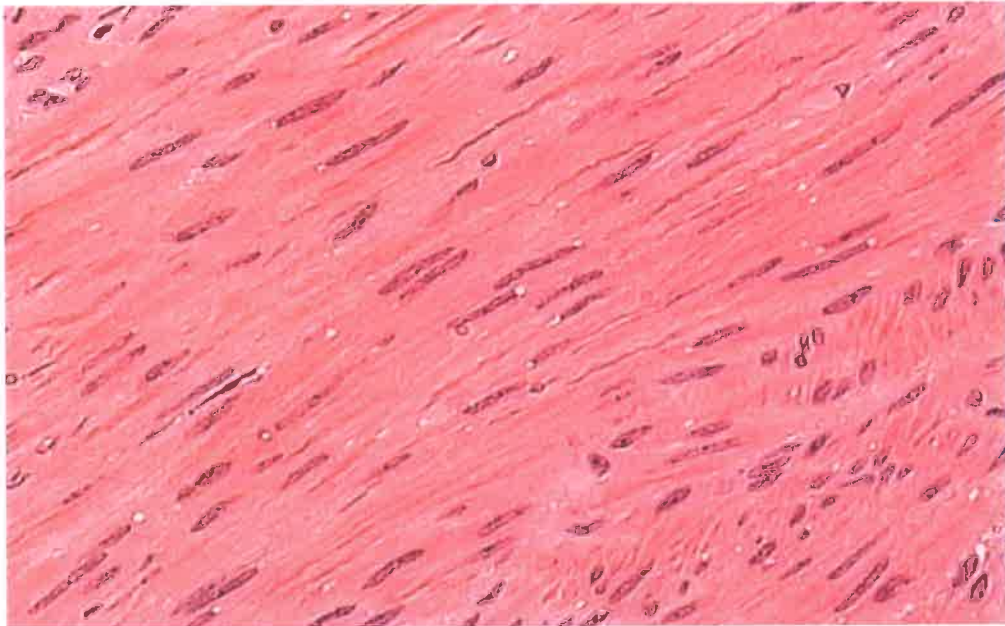
Histology Lab Part 7: Slide 46

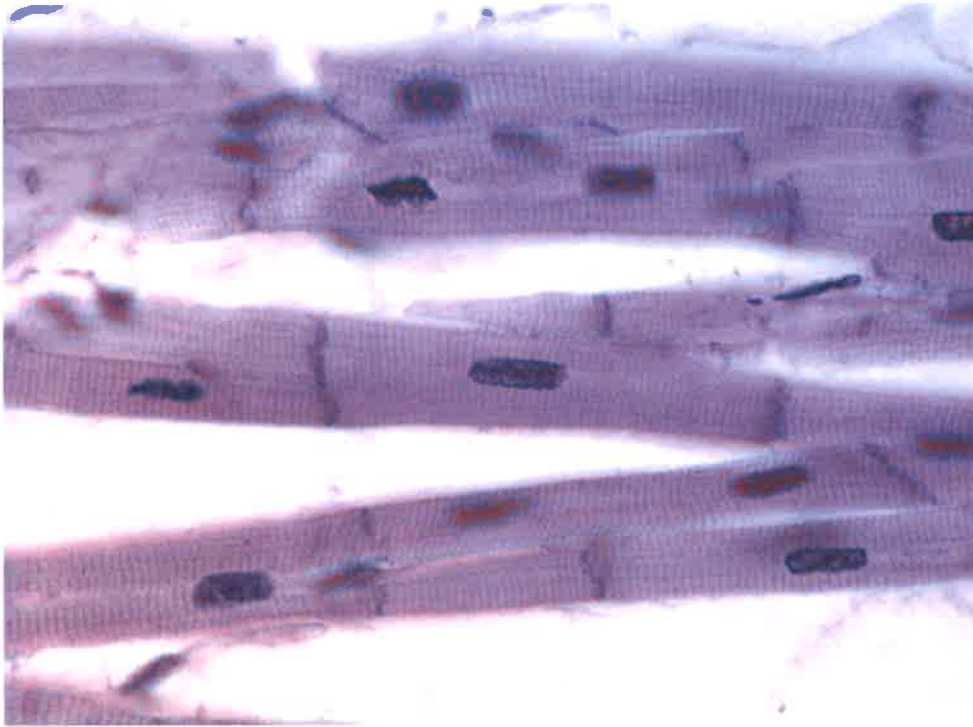Skeletal Muscle



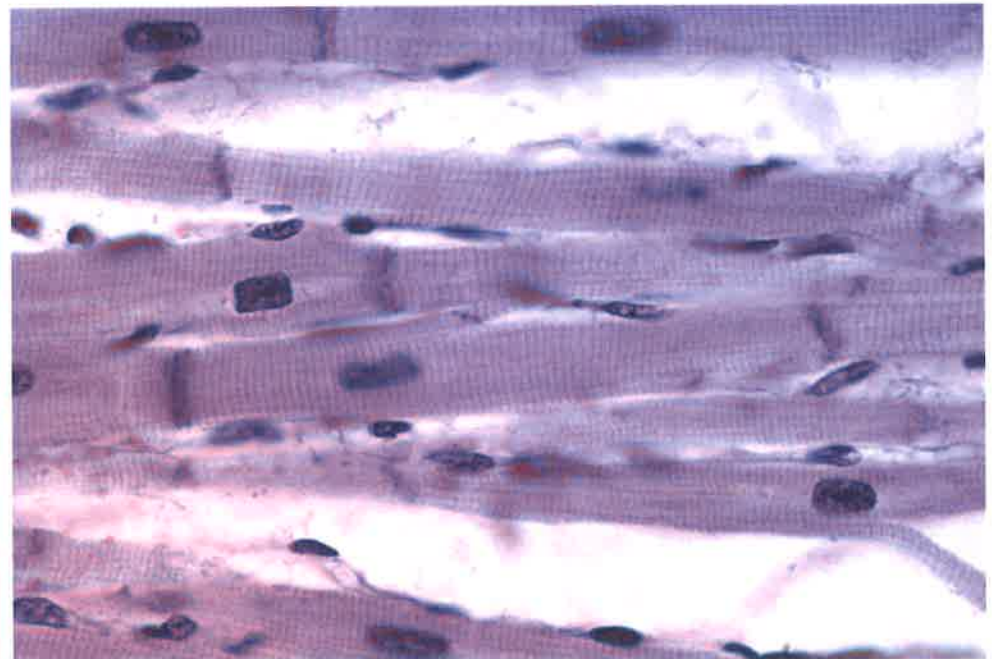
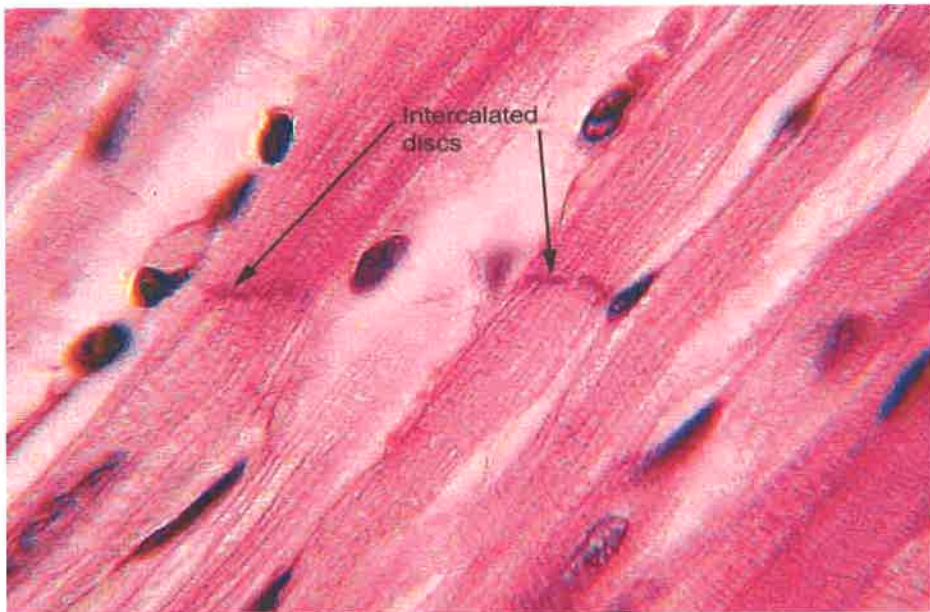
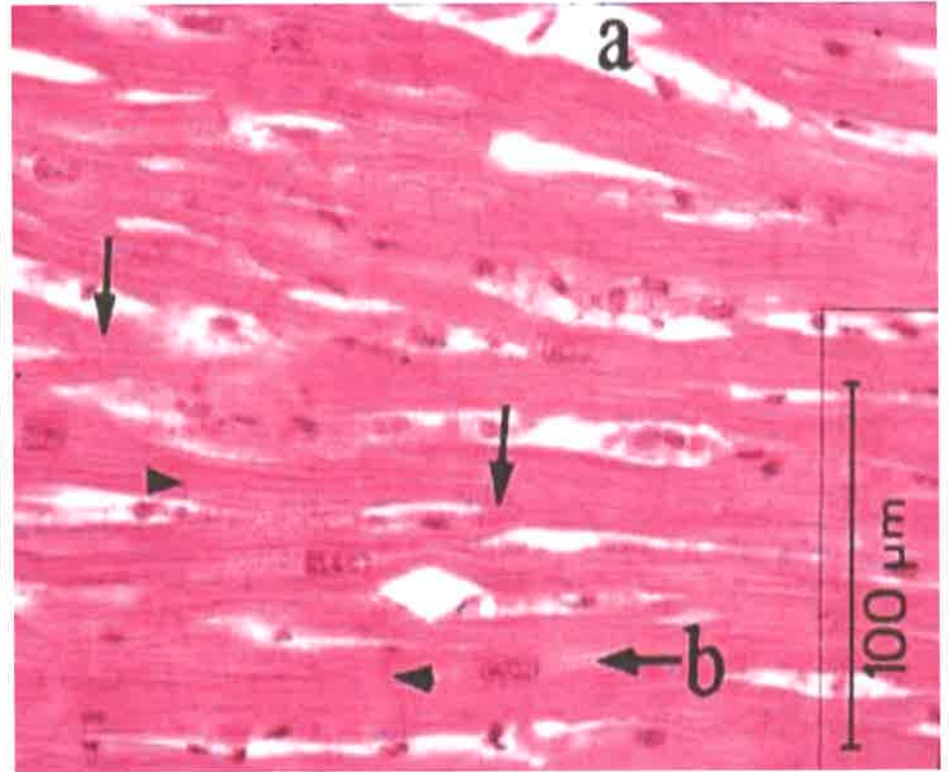


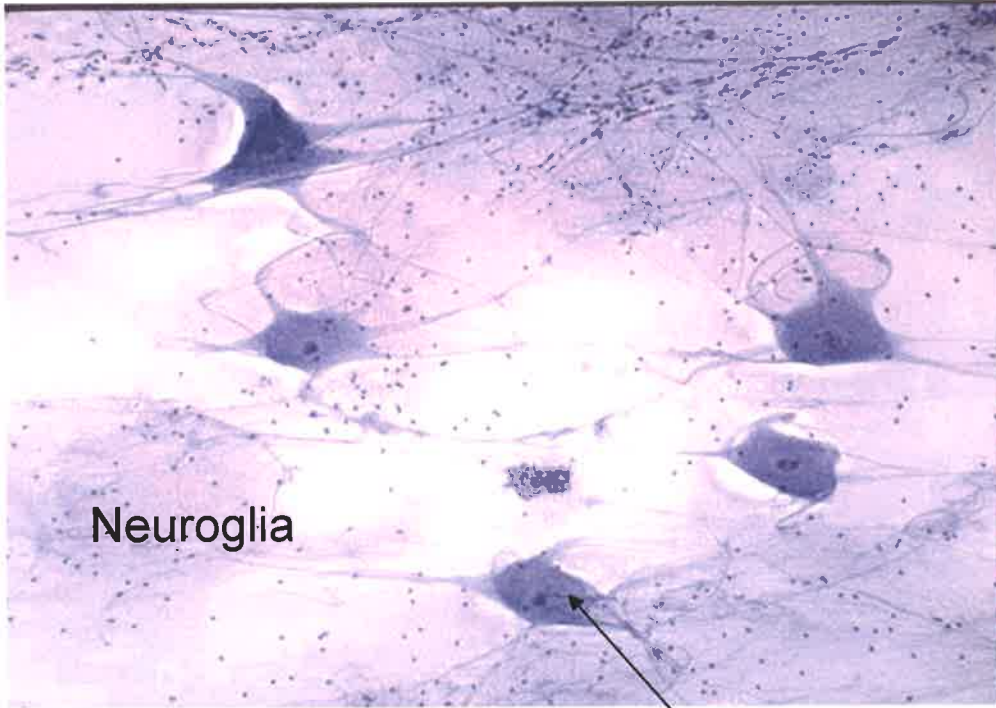
Smooth Muscle



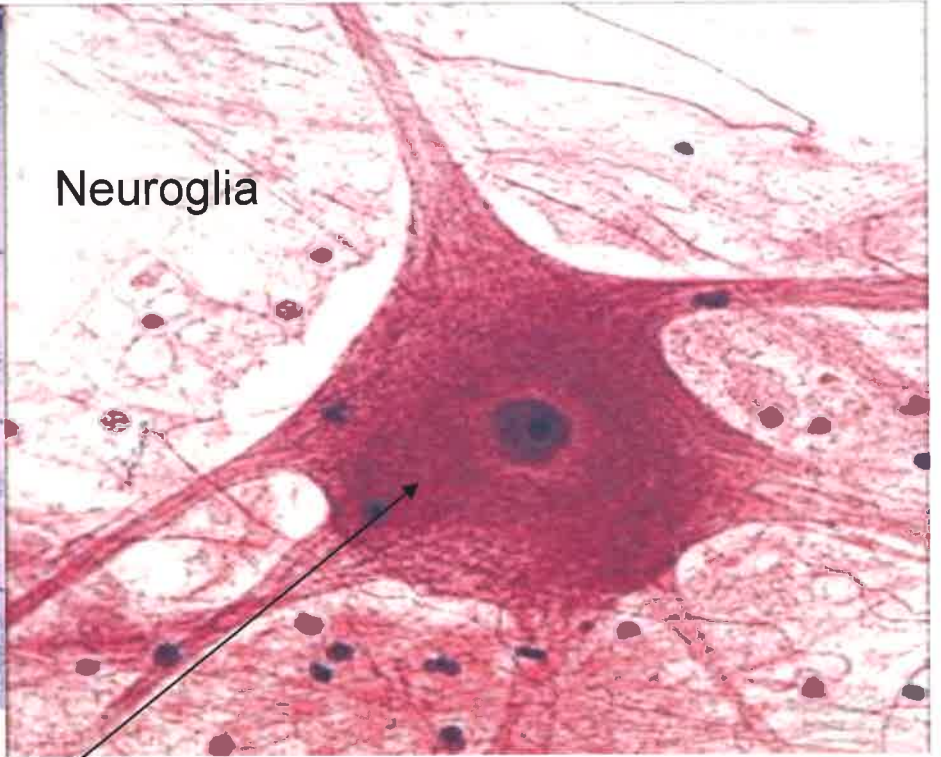


Cardiac Muscle





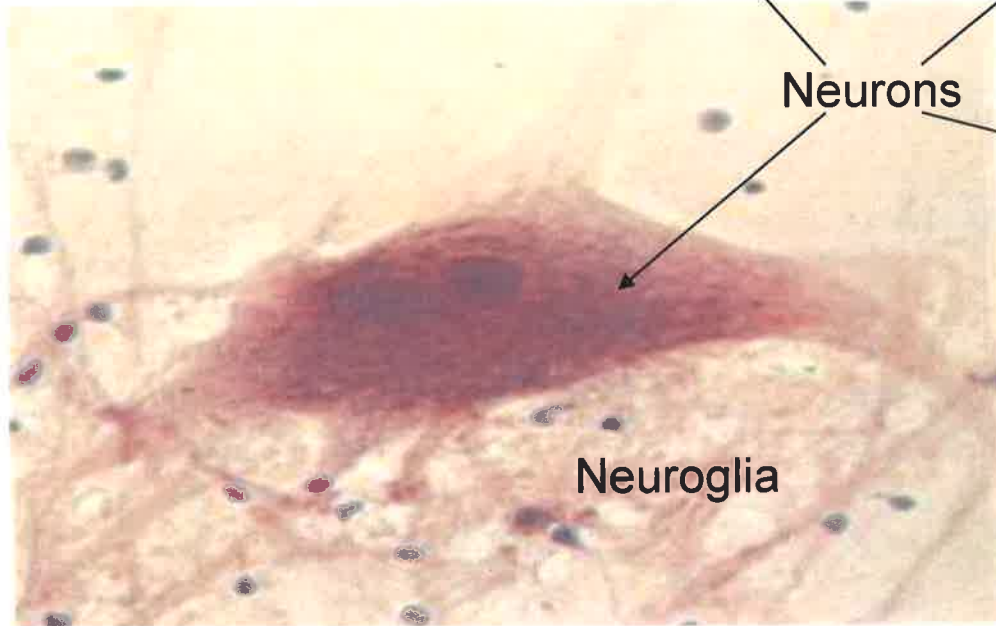
Neuroglia



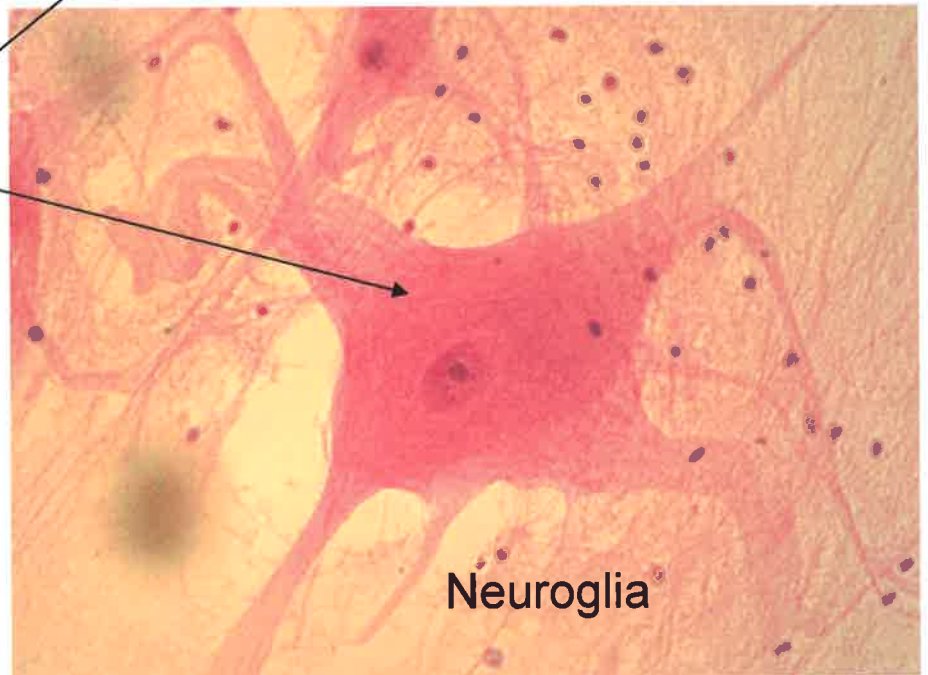
Neuroglia

Nervous Tissue

Neurons



Neuroglia



Neuroglia